Temel EKG

SUNUM PLANI

EGK Tarihçesi

Kalp Kası Fizyolojisi

EKG Derivasyonları

Elektriksel iletim

William Gilbert 1600 yüzyıl canlı dokusunda elektrik olduğunun tesbiti



Luigi Galvani : 1780
Deneysel olarak kas kasılmasının elektrik deşarjı ile olduğunu göstermiştir.



Augustus De'sire' Waller 1887 de ilk defa insanda kalp elektriksel aktivitesini göstermiştir.



Willem Einthoven 1903 yılında tel şeklinde galvanometreyi buldu ve bunu yazdırmayı başardı.

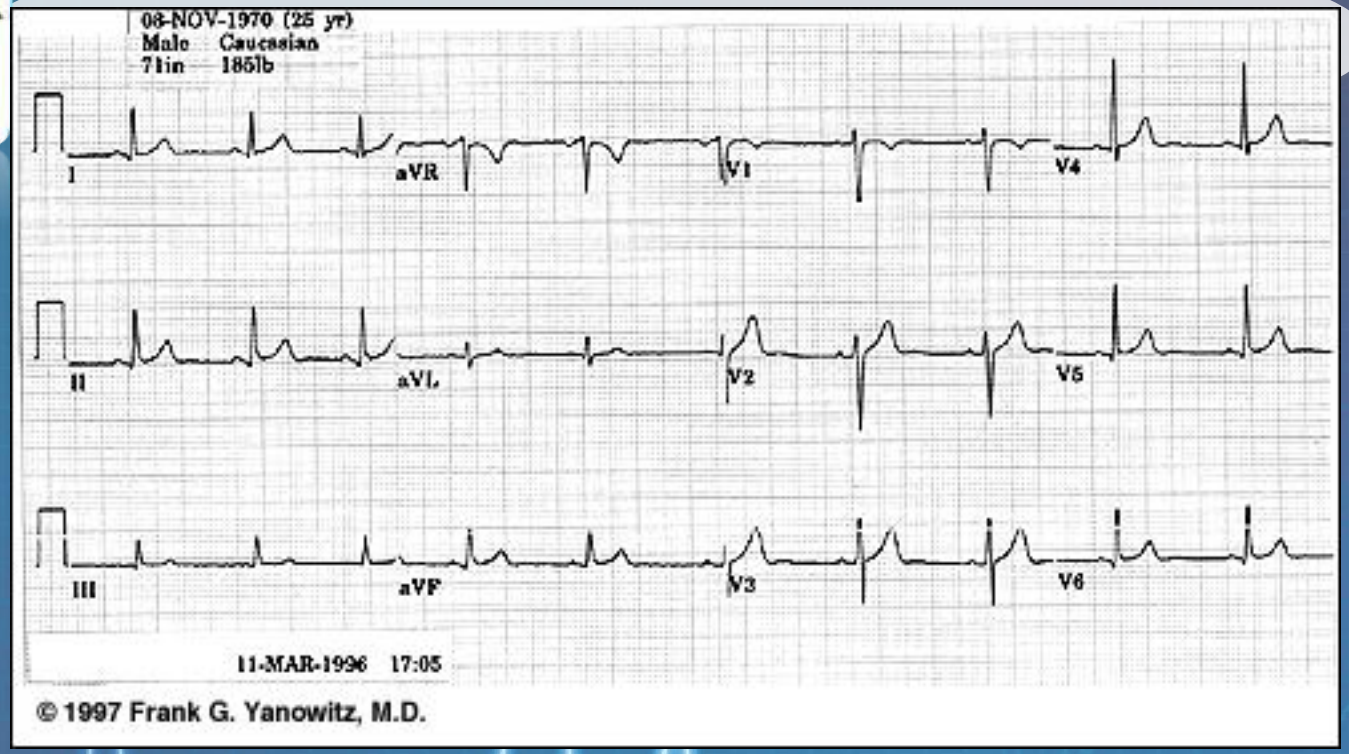

Willem Einthoven tarafından 1895 de EKG dalgalarına isimler verildi P,Q,R,S,T

Charles Wolferth ve Francis Wood tarafından 1932 yılında ilk defa göğüs elektrotlarını kullanılmıştır.





Dr. Walter B. Miles, Boston. June 18th, 1920

Electrocardiogram taken with Einthoven's original string galvanometer.
(See the instrument on the corner of the brick pillar.)

Lead I

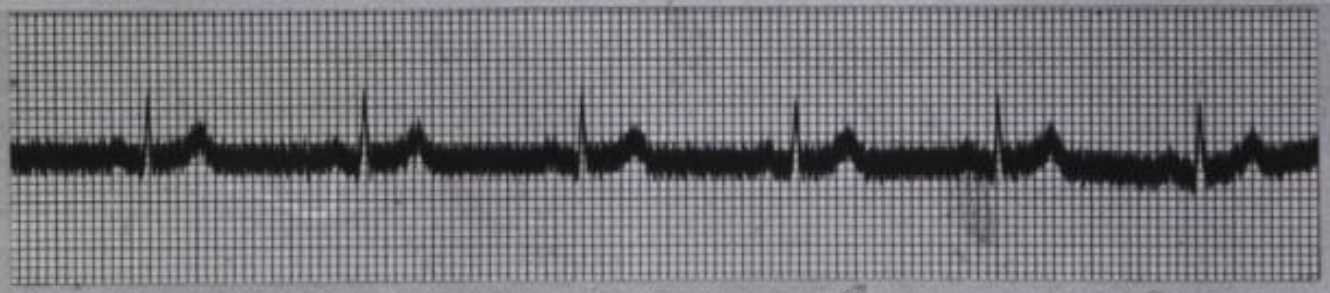

abs. 1 div. = 0,04 sec.
ordin. 1 " = 10^{-4} Volt

With kind regards
of W. Einthoven

Kalp kasının fizyolojik özellikleri

Kalp kası 4 önemli fizyolojik özelliğe sahiptir:

1. Uyarılabilme (Batmotropi),
2. Kasılabilme (İnotropi),
3. Otonomi (otoritmisite - Kronotropi),
4. İletebilme (Dromotropi).

Kalp Kasında Aksiyon Potansiyeli

Faz 0: Voltaj-kapılı Na+ kanalları açılır Na+ girişi artar ve depolarizasyon gerçekleşir.

Faz 1: AP pik değere ulaştığında (+20 mV), voltage-gated Na+ kanalları kapanır, K+ kanallarının açılması ile K+ çıkışı artar. Hızlı Depolarizasyon gerçekleşir

Faz 2: Plato Fazı. Bu fazda hızlı K+ kanalları kapanır ve K+ çıkışı azalır, Ca2+ permeabilitesi artar. (Ca2+ kanallarının açılması ile)

Faz 3: Geç Repolarizasyon Ca2+ kanallarının kapanması ve yavaş K+ kanallarının açılması ile sona erer.

Faz 4: K+'un dışarı çıkması ile membran potansiyeli -90 mV düzeyine geri döner.

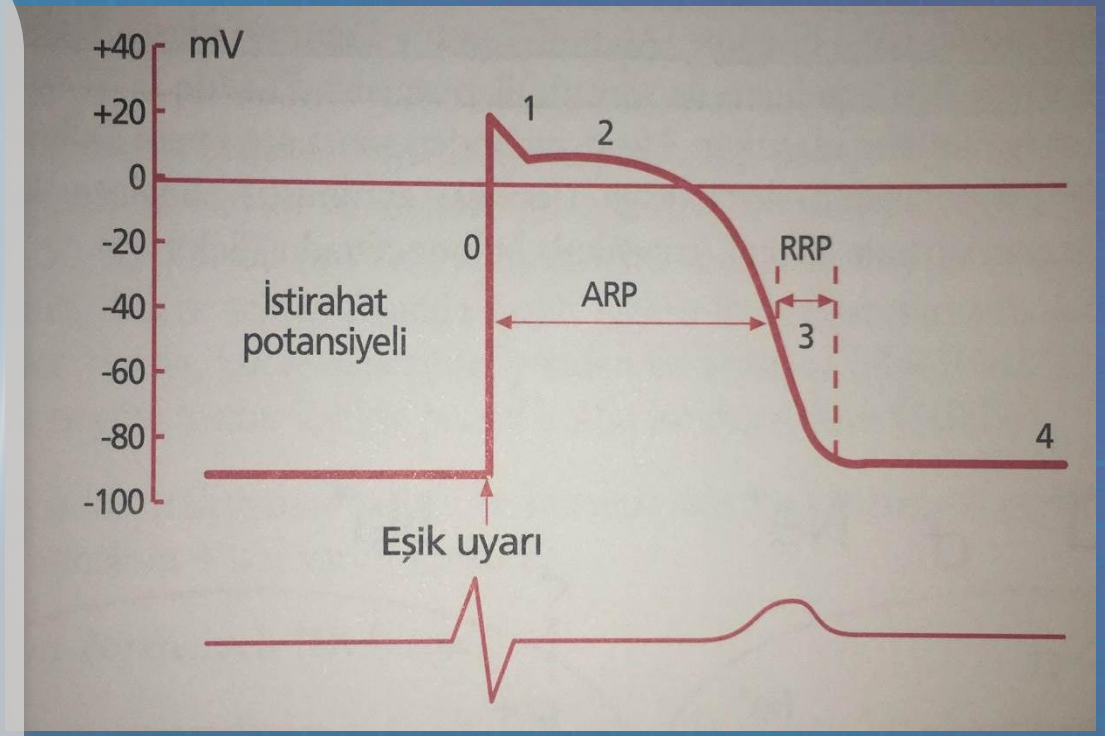

Refrakter Periyot

- **Mutlak refrakter periyot:** Kalp kasları yüksek şiddette uyarılara bile duyarsızdır, hiçbir şekilde yanıt vermez
- **Rölatif refrakter periyot :** Kas lifleri birbiri ardına verilen uyarılara karşı cevap verebilir düzeye gelebilir

Refrakter periyot kalp kasını diyastolde kalbe yeterli kan dolması için hızlı ve düzensiz ritimlerden korur.

Unipolar Derivasyonlar

- aVR; Sağ kol
- aVL; Sol kol
- aVF; Sol bacak

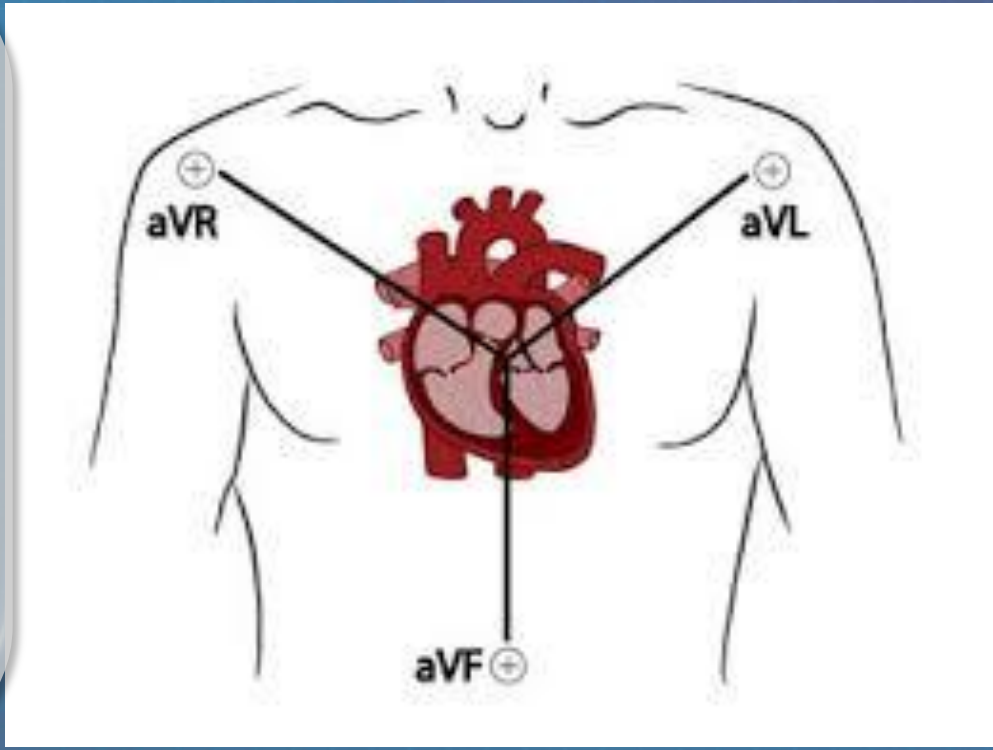

Bipolar Derivasyonlar

- DI; sağ kol-sol kol
- DII; sağ kol-sol bacak
- DIII; sol kol-sol bacak

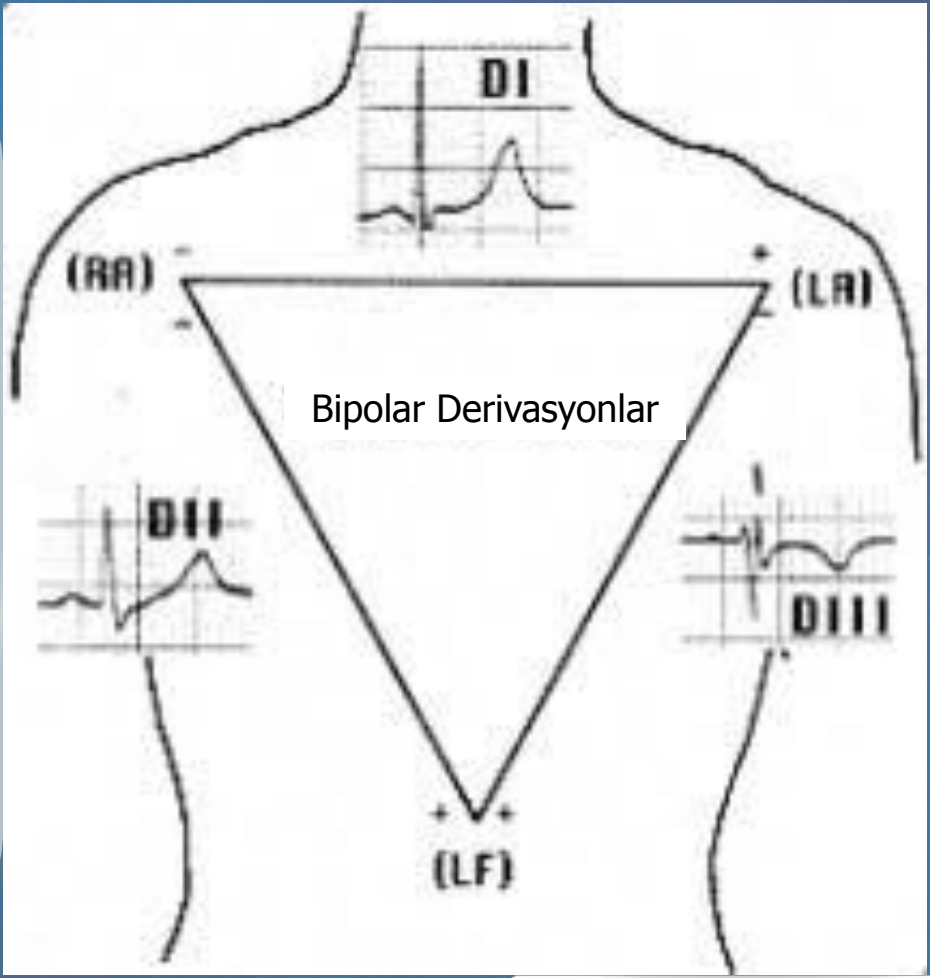

Ekstremite Derivasyonları

Unipolar ve bipolar (Ekstremite) derivasyonlarının koronal düzlemde izdüşümü

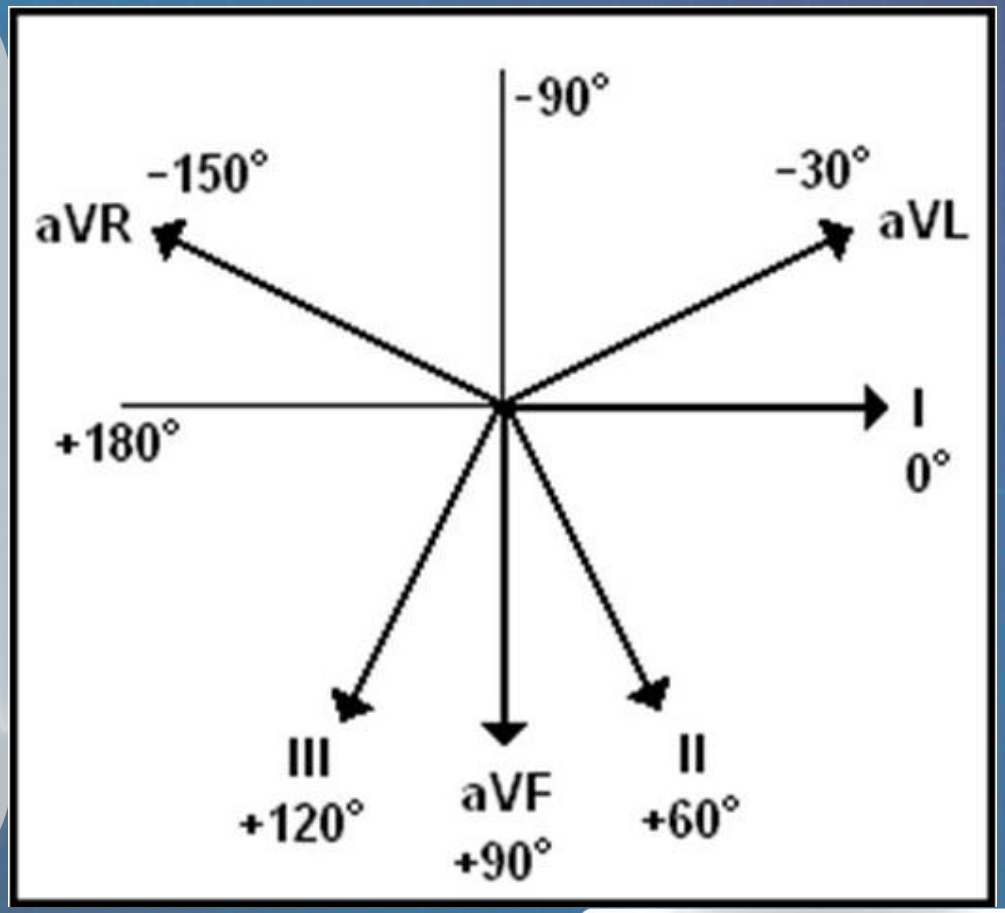

Göğüs derivasyonları

V1: Sternumun sağında 4. interkostal aralık,

V2: Sternum solu 4. interkostal aralık,

V3: V2-V4 ortası

V4: 5. interkostal aralık – midklaviküler hat

V5: 5. İnterkostal aralık sol ön koltuk (aksilla) çizgisi

V6: 5. İnterKostal aralık sol orta koltuk (aksilla) çizgisi

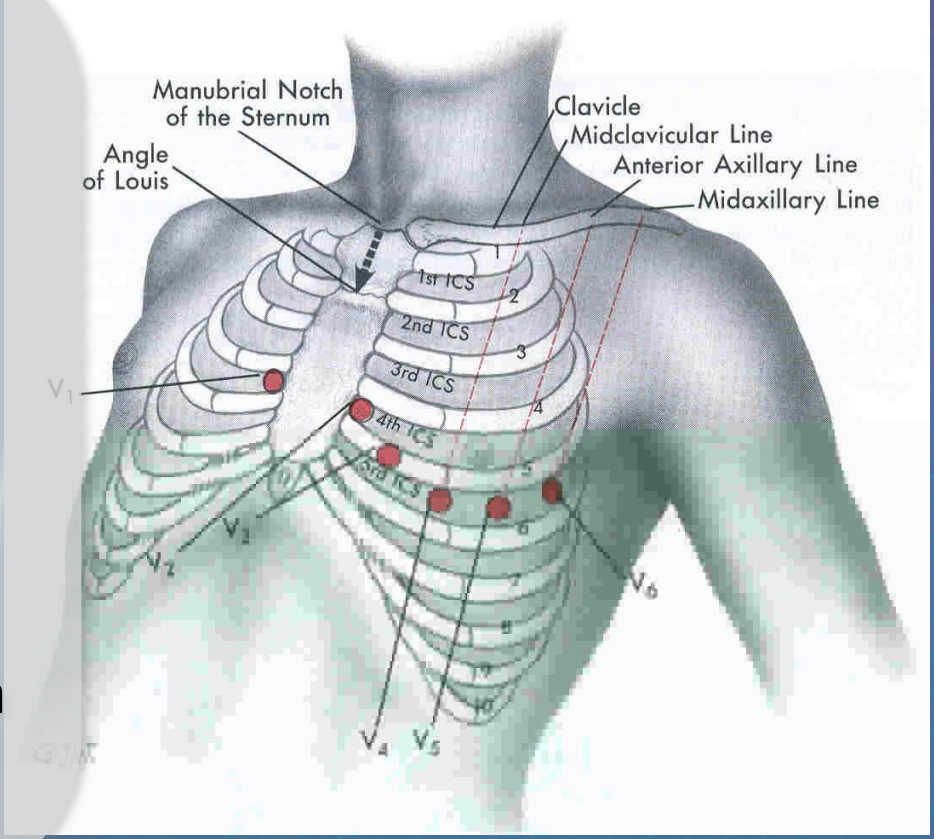

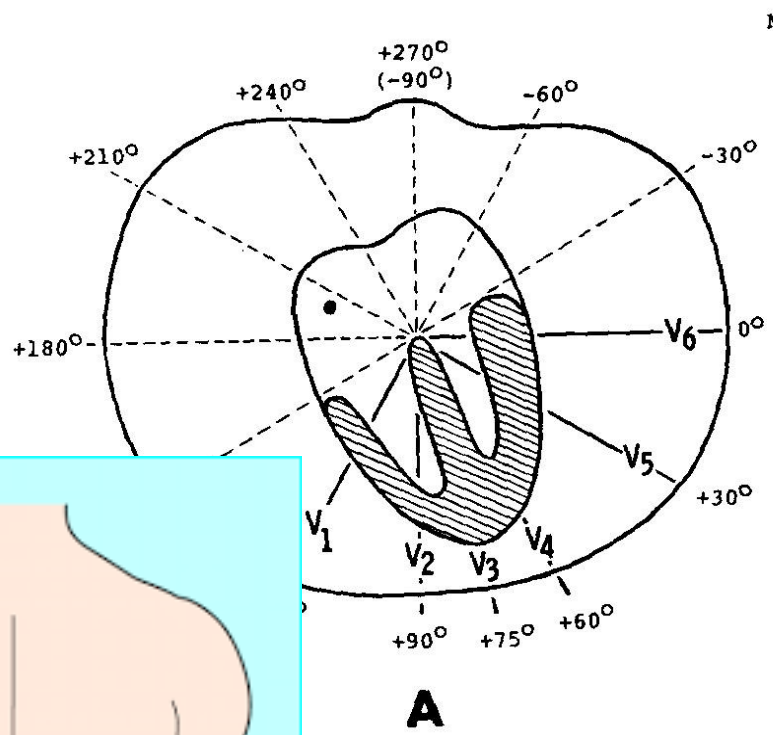
+270°
(-90°)
+240°
-60°
+210°
-30°
+180°
0°
V6
V5
+30°
V1
V2
V3
V4
+90°
+75°
+60°
A

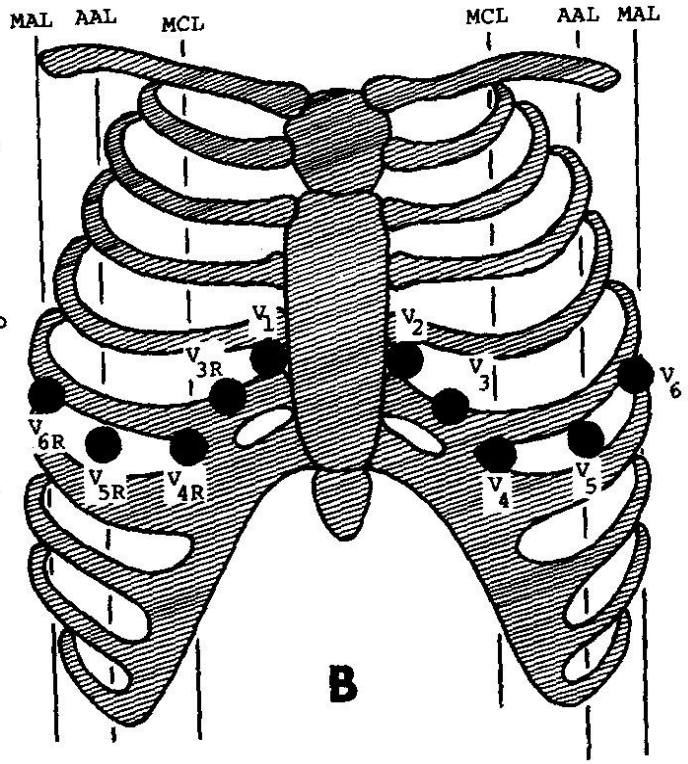
MAL
AAL
MCL
MCL
AAL
MAL
V1
V2
V3R
V3
V6
V6R
V5R
V4R
V4
V5
B

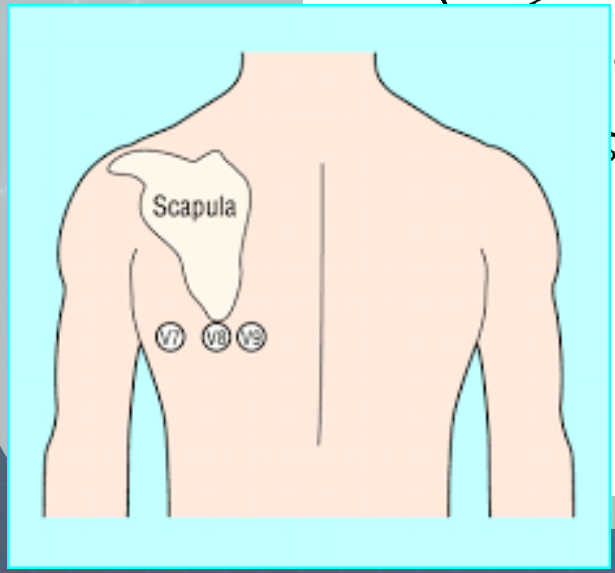
Scapula
V7
V8
V9

Vektörler

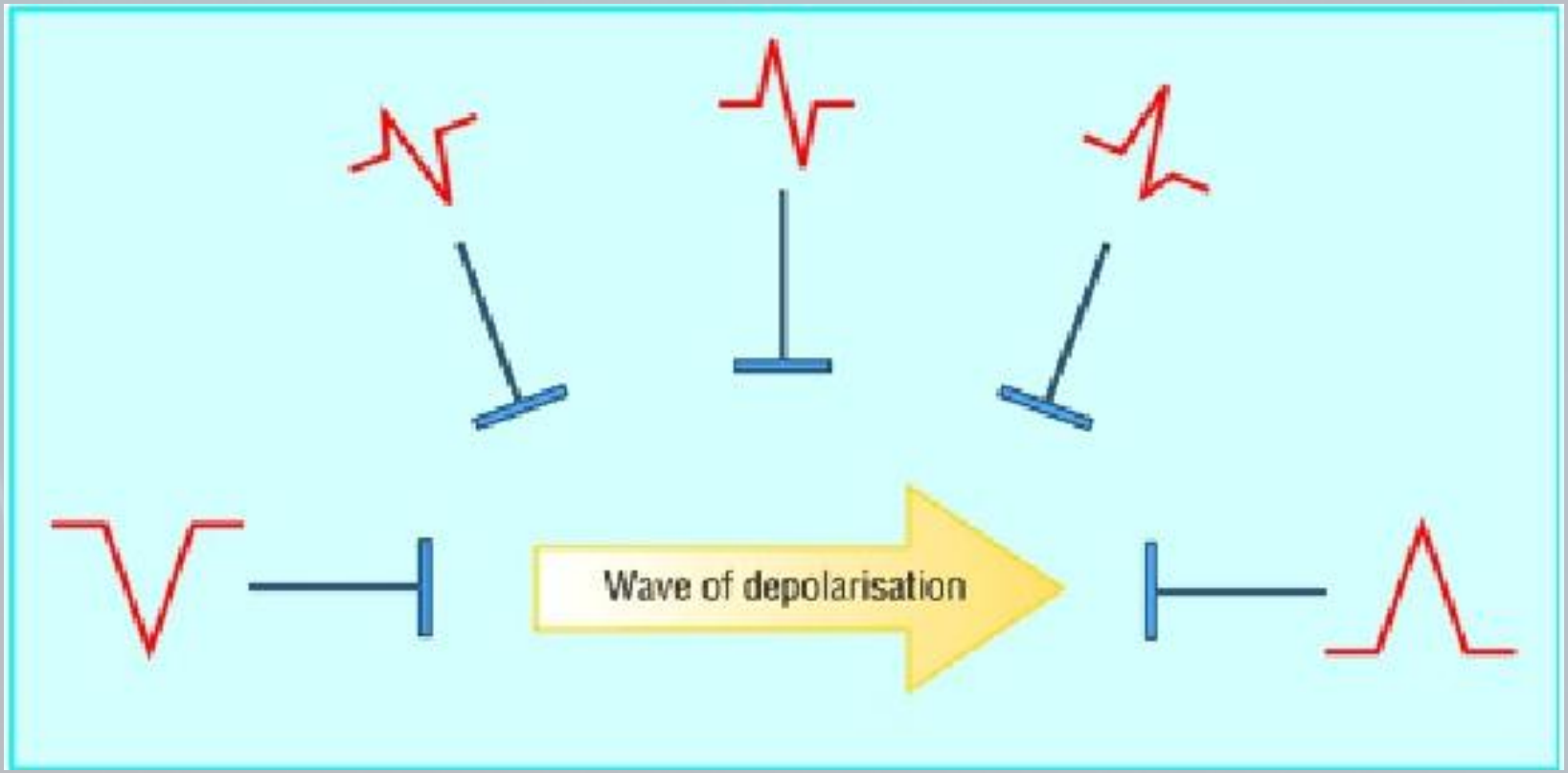

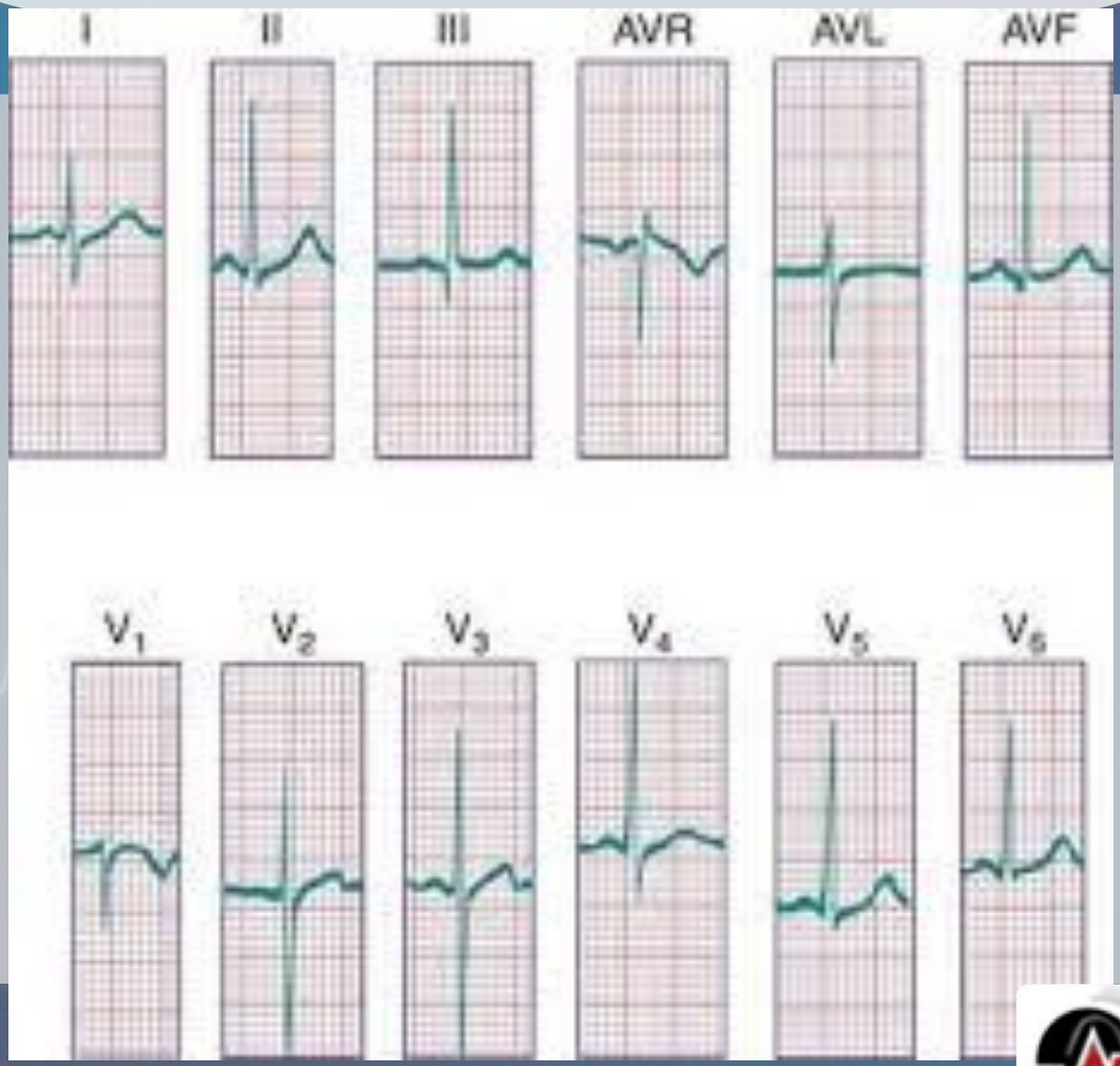
I
II
III
AVR
AVL
AVF
V1
V2
V3
V4
V5
V6

Kardiyak aks

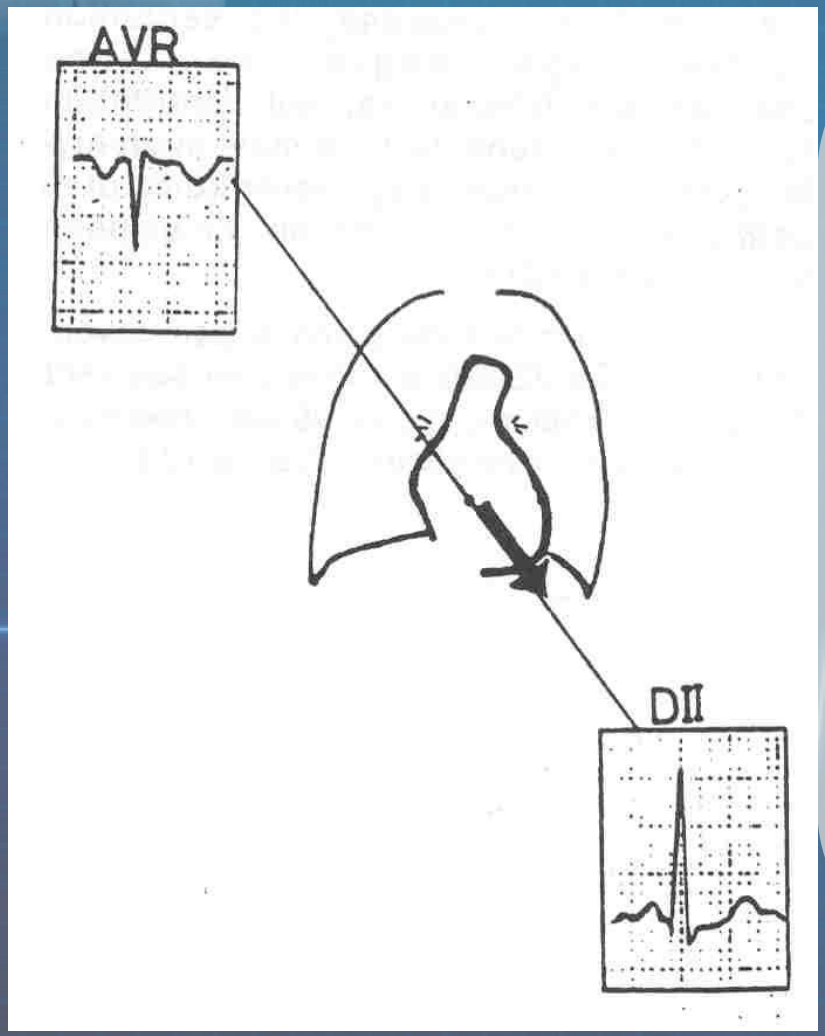

- Sağdan sola
- Yukarıdan aşağıya
- Yaklaşık 45º lik bir açı ile uzanır

DII derivasyonuna paraleldir.

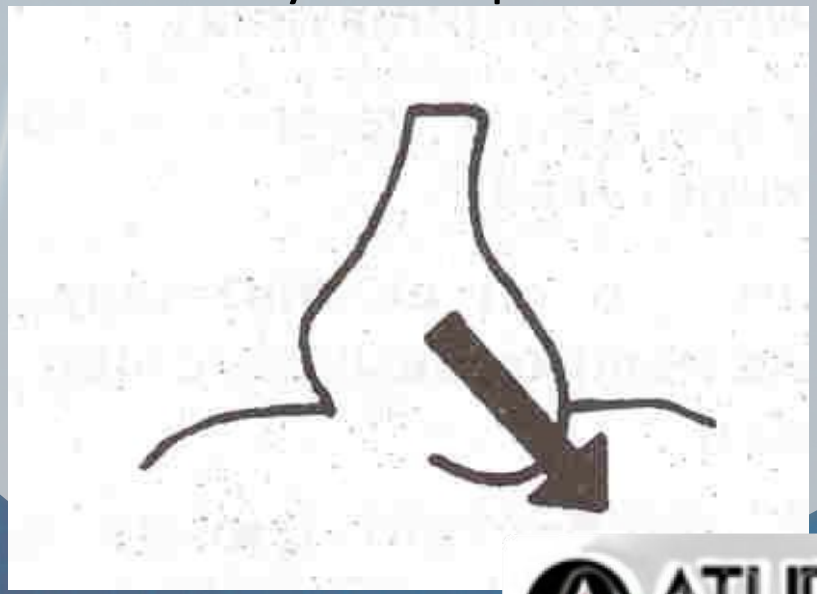

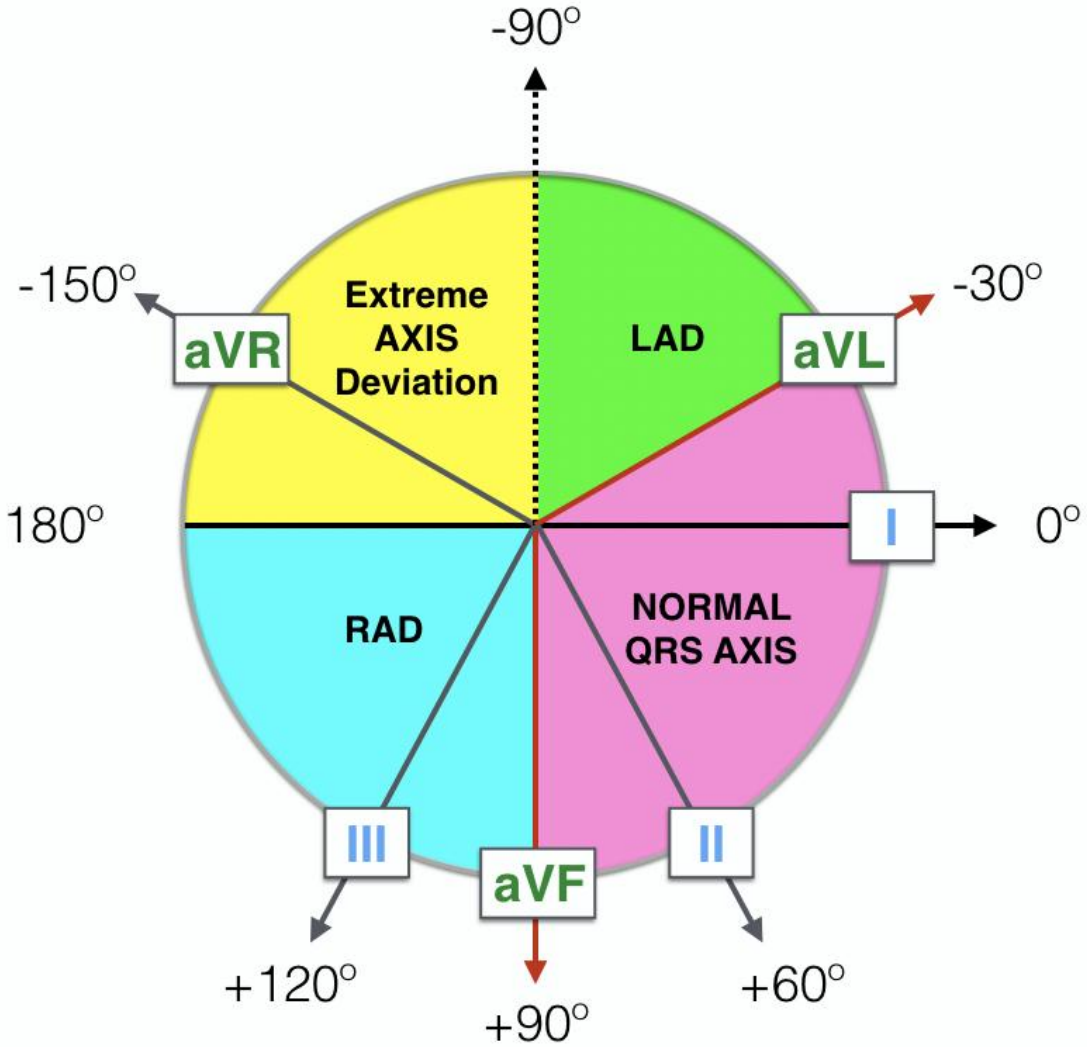
-90°
-150°
-30°
Extreme
AXIS
Deviation
LAD
aVR
aVL
180°
I
0°
RAD
NORMAL
QRS AXIS
III
aVF
II
+120°
+90°
+60°

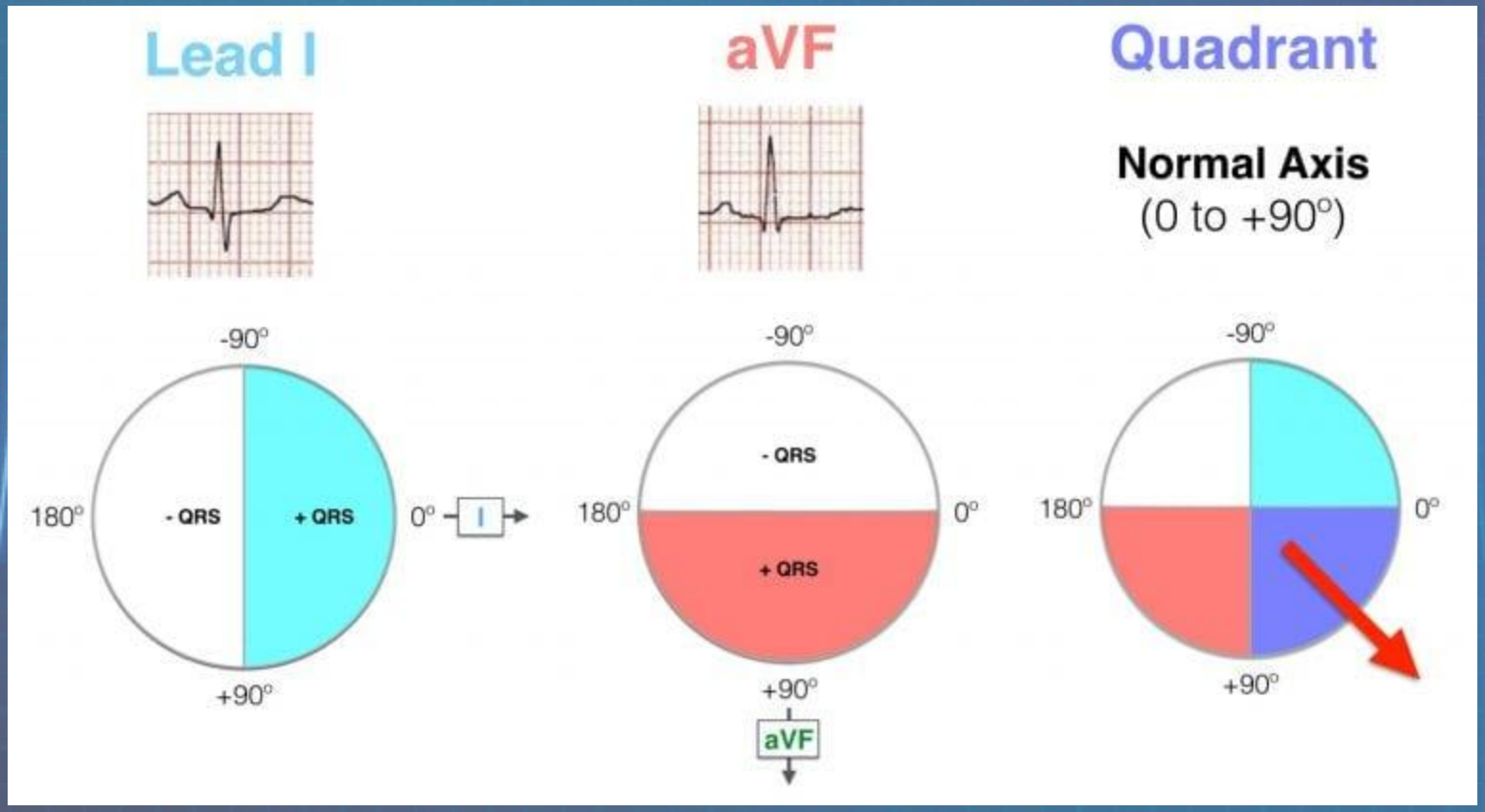
Lead I
aVF
Quadrant
Normal Axis
(0 to +90°)
-90°
180°
- QRS
+ QRS
0°
I
+90°
-90°
- QRS
180°
0°
+ QRS
+90°
aVF
-90°
180°
0°
+90°

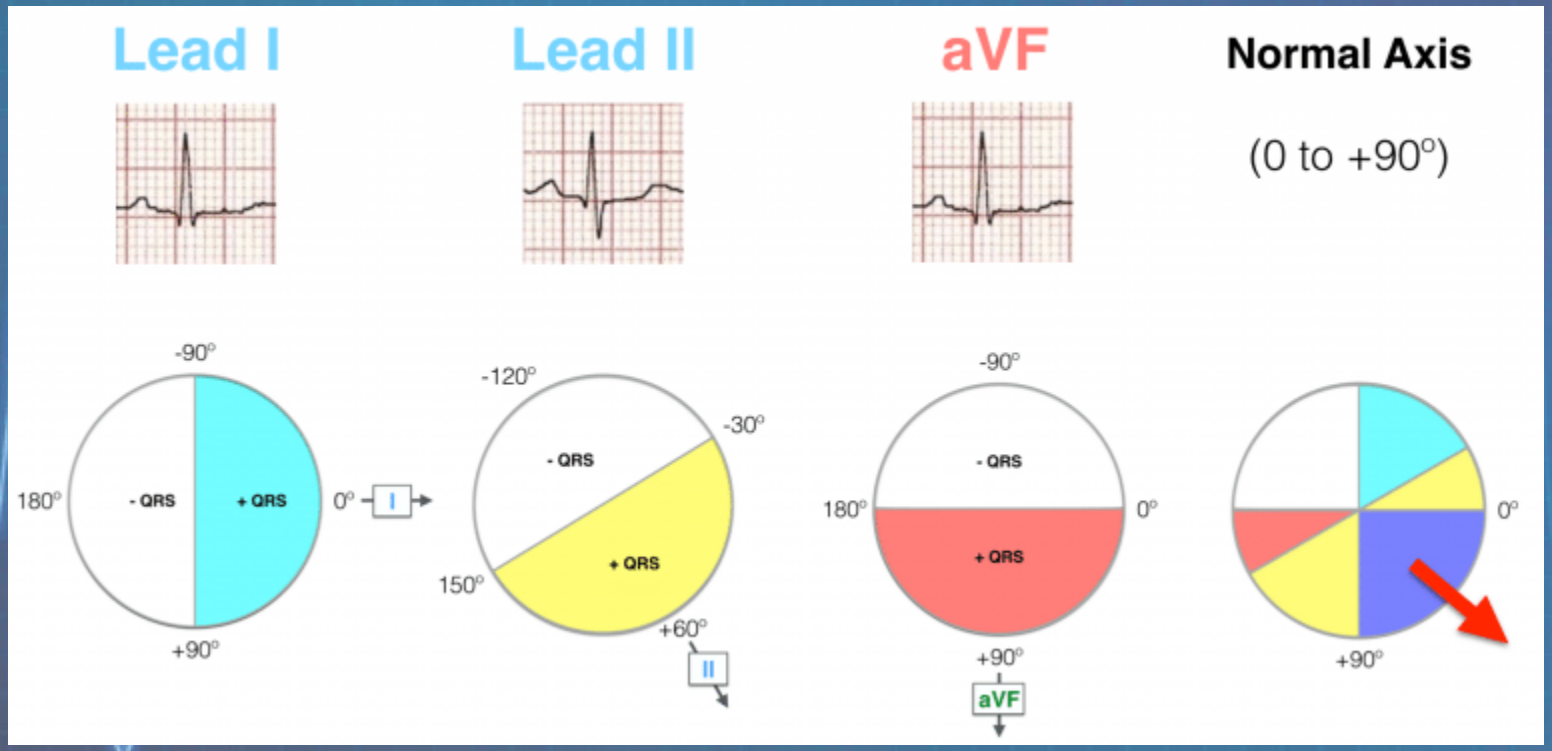
Lead I
Lead II
aVF
Normal Axis
(0 to +90°)
-90°
180°
- QRS
+ QRS
0°
I
+90°
-120°
-30°
- QRS
+ QRS
150°
+60°
II
-90°
- QRS
180°
0°
+ QRS
+90°
aVF
0°
+90°

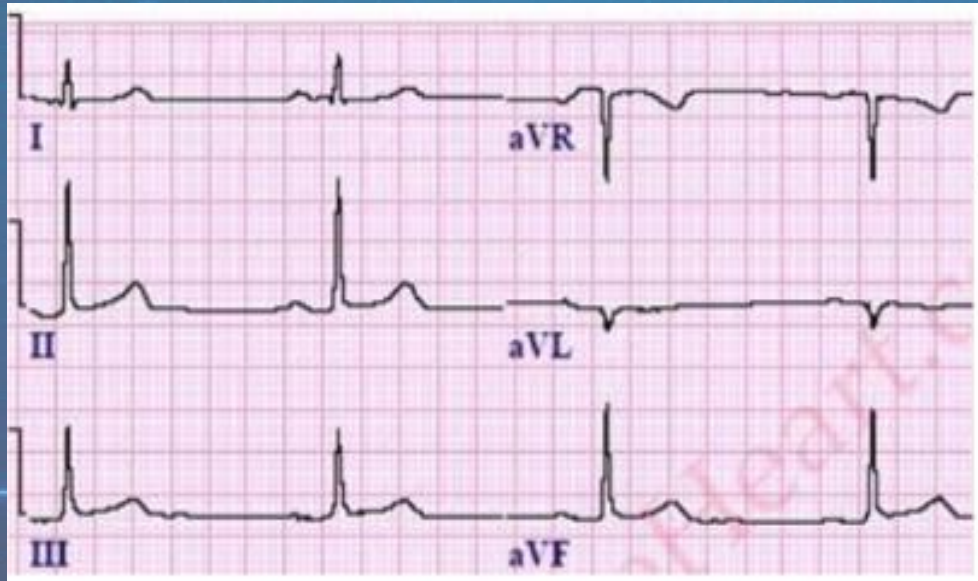

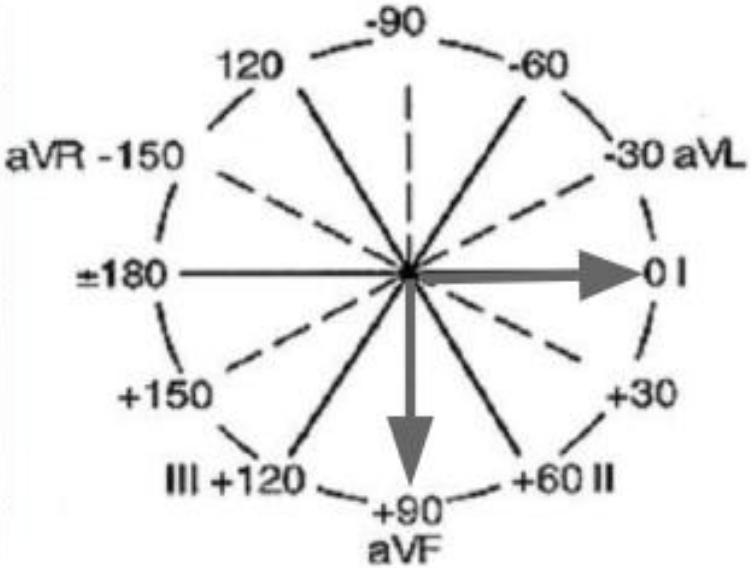

Normal QRS Axis: Positive in Lead I and aVF

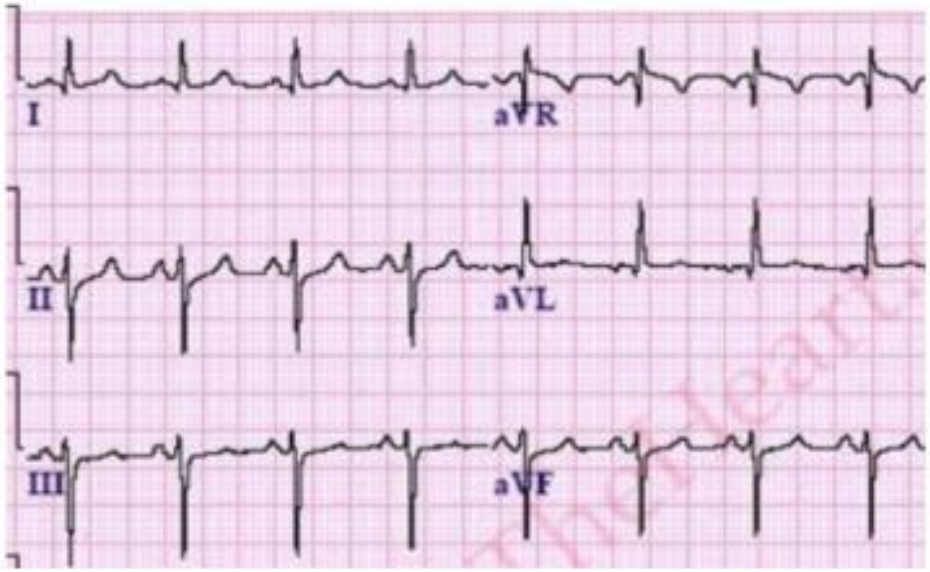

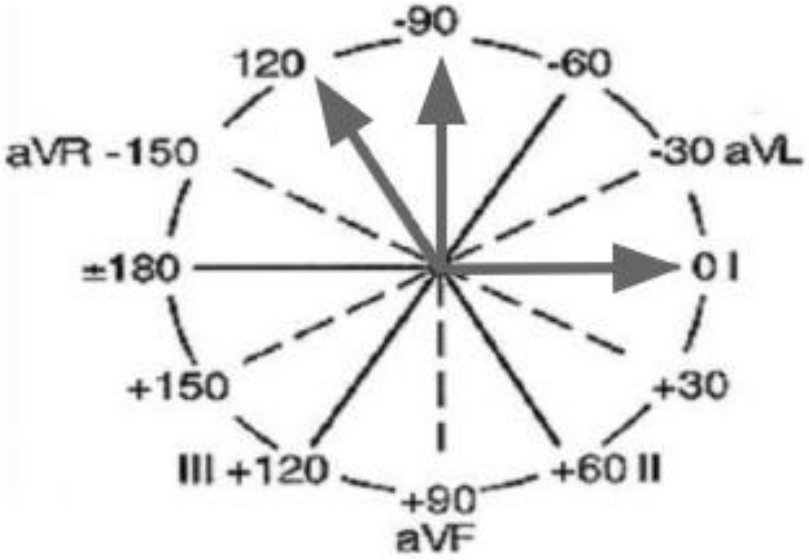

Left Axis Deviation of the QRS Axis:
Positive in Lead I, negative in lead aVF and lead II

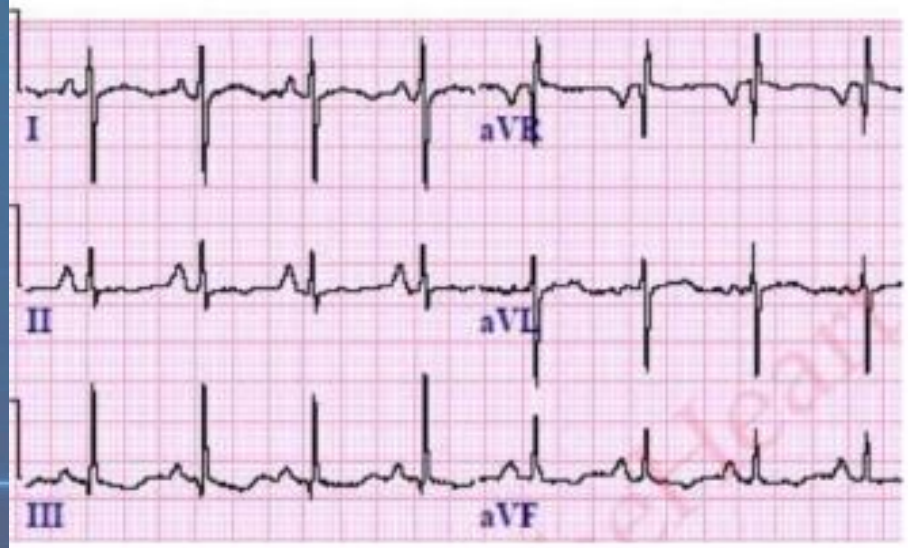

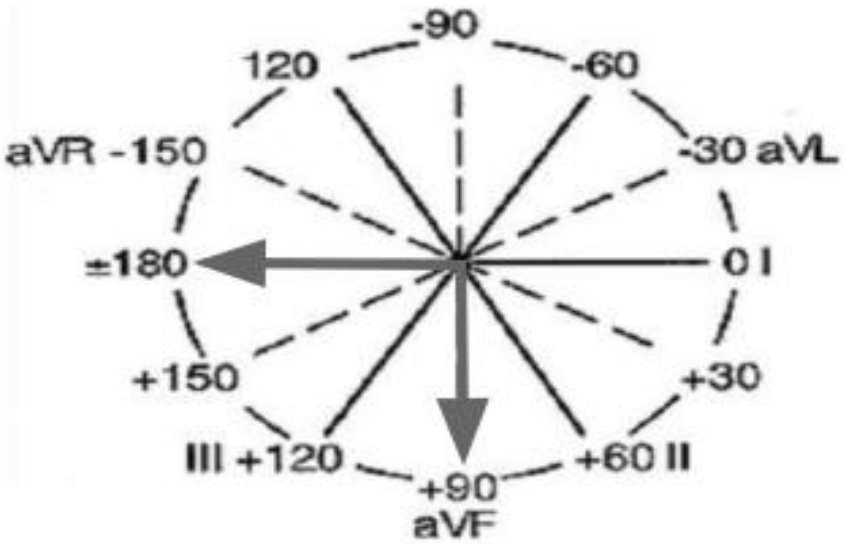

Right Axis Deviation of the QRS Axis:
Negative in Lead I and positive in lead aVF

Depolarizasyon/Repolarizasyon & EKG deki değişimler

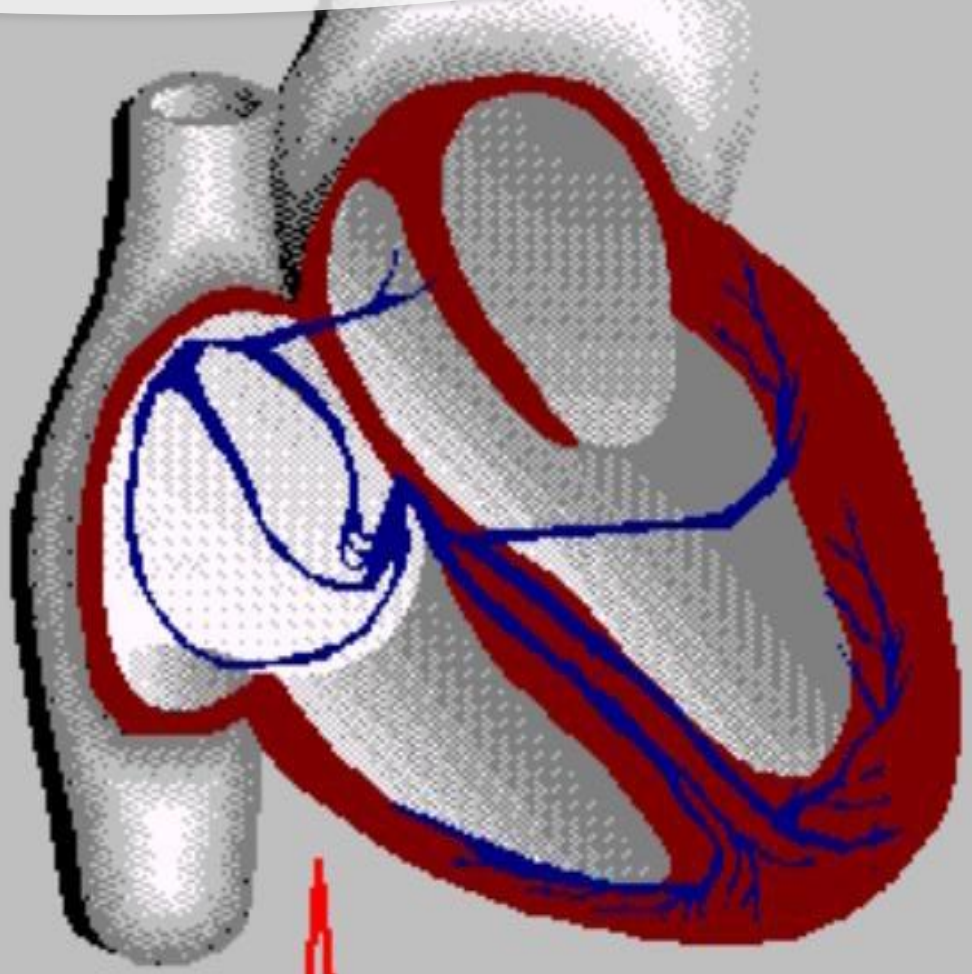

Atriyum depolarizasyonu

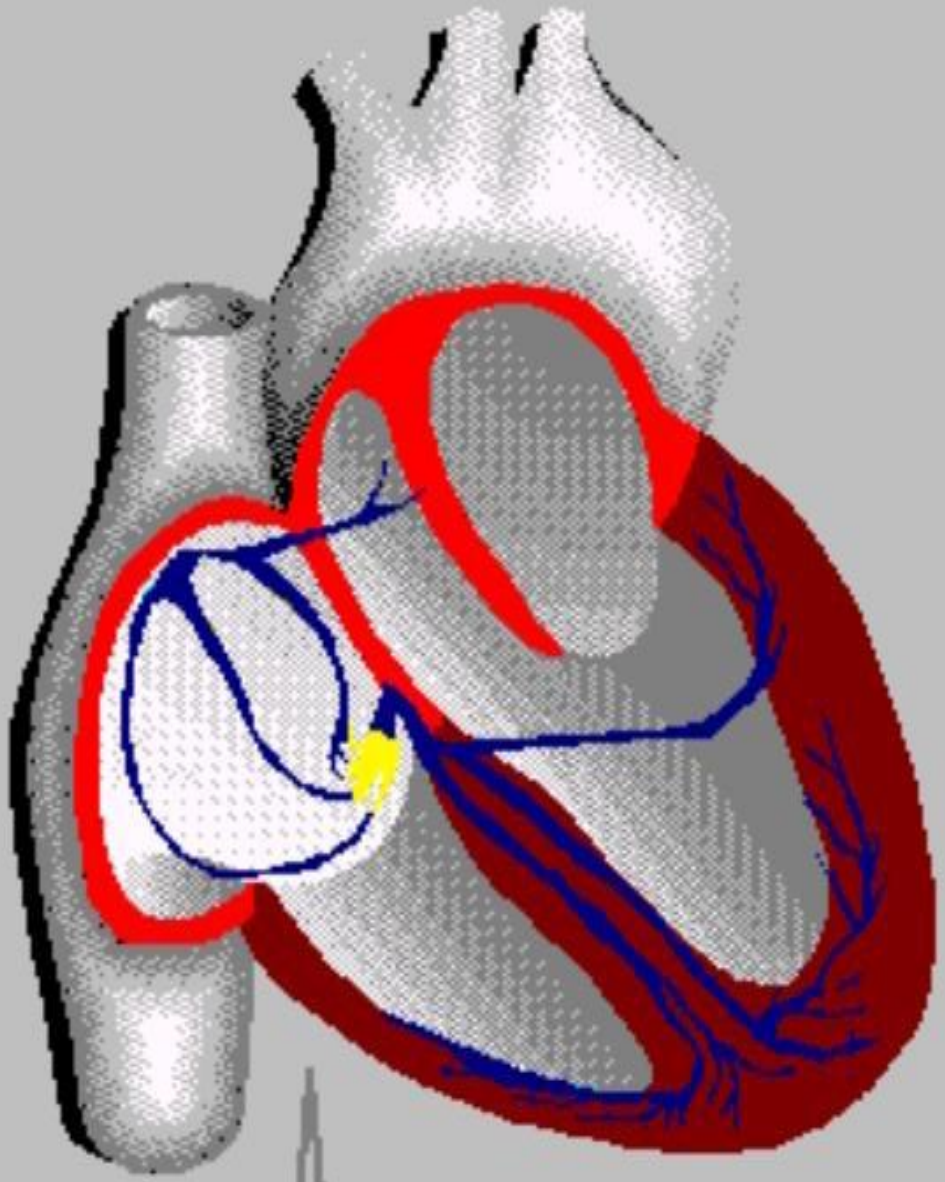

AV ileti

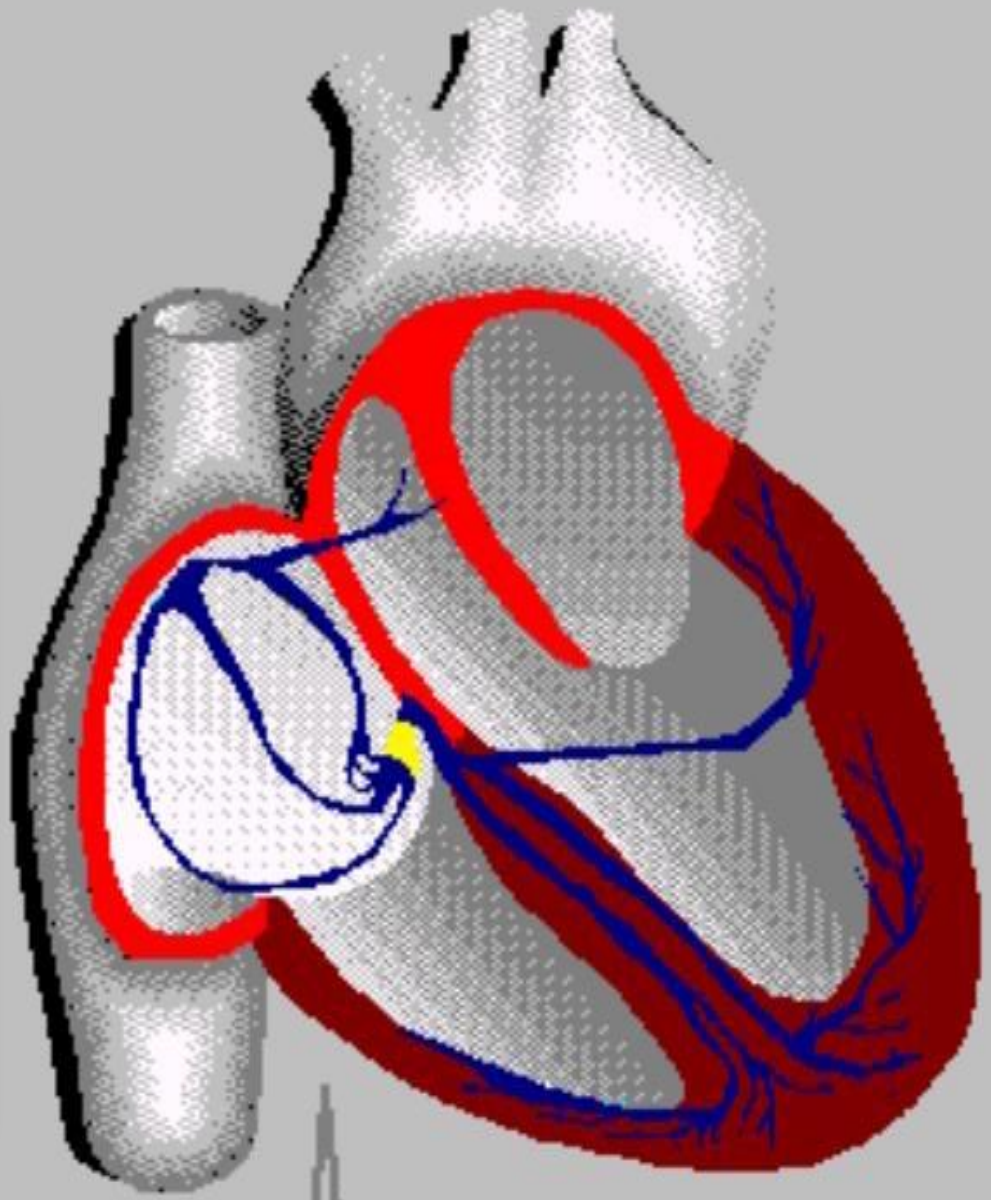

ATOK
Acil Tıp Okulu

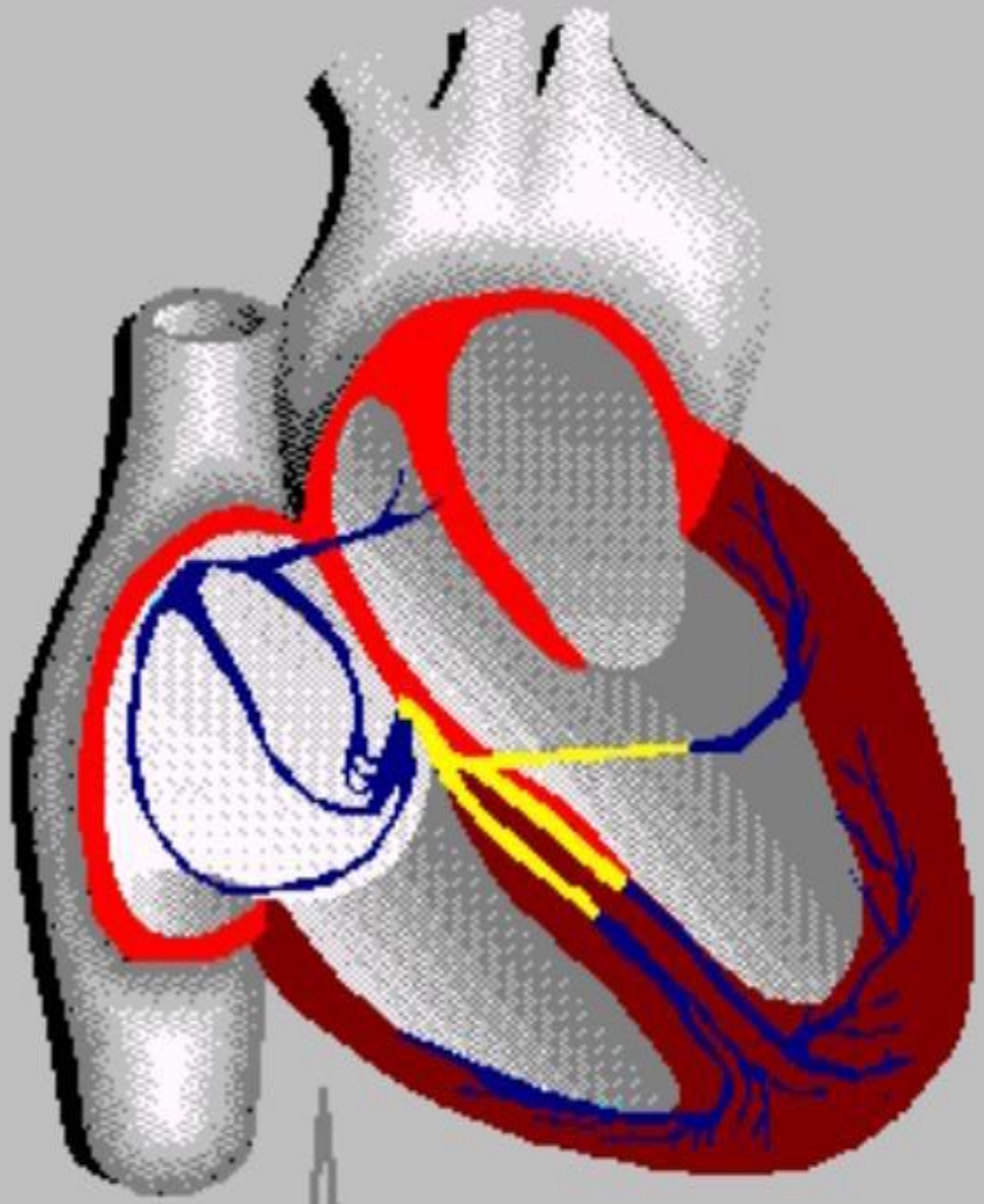

ATUDER
Acil Tıp Uzmanları Derneği

Septumun soldan sağa doğru depolarizasyonu

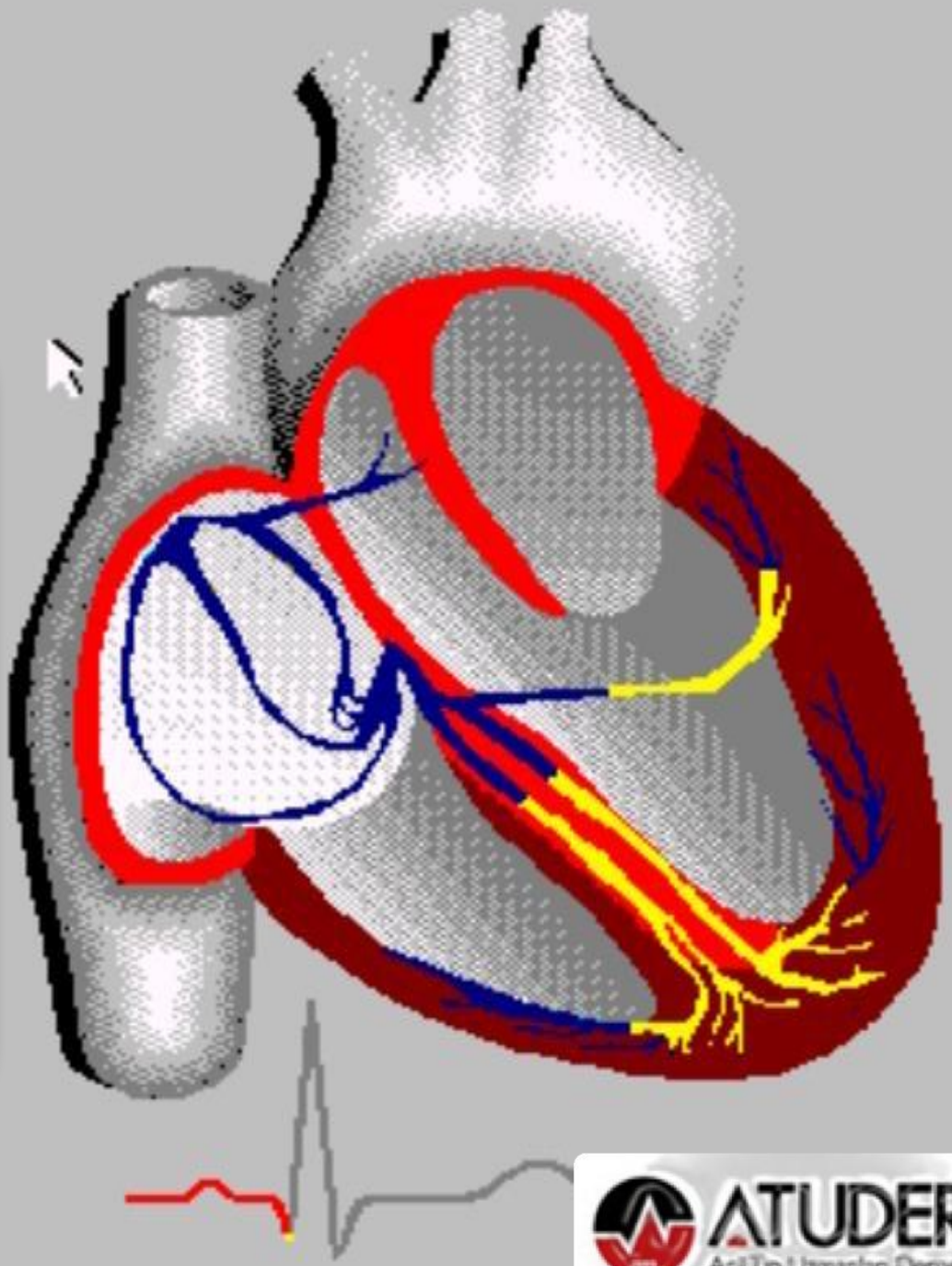

Ventrikül depolarizasyonu

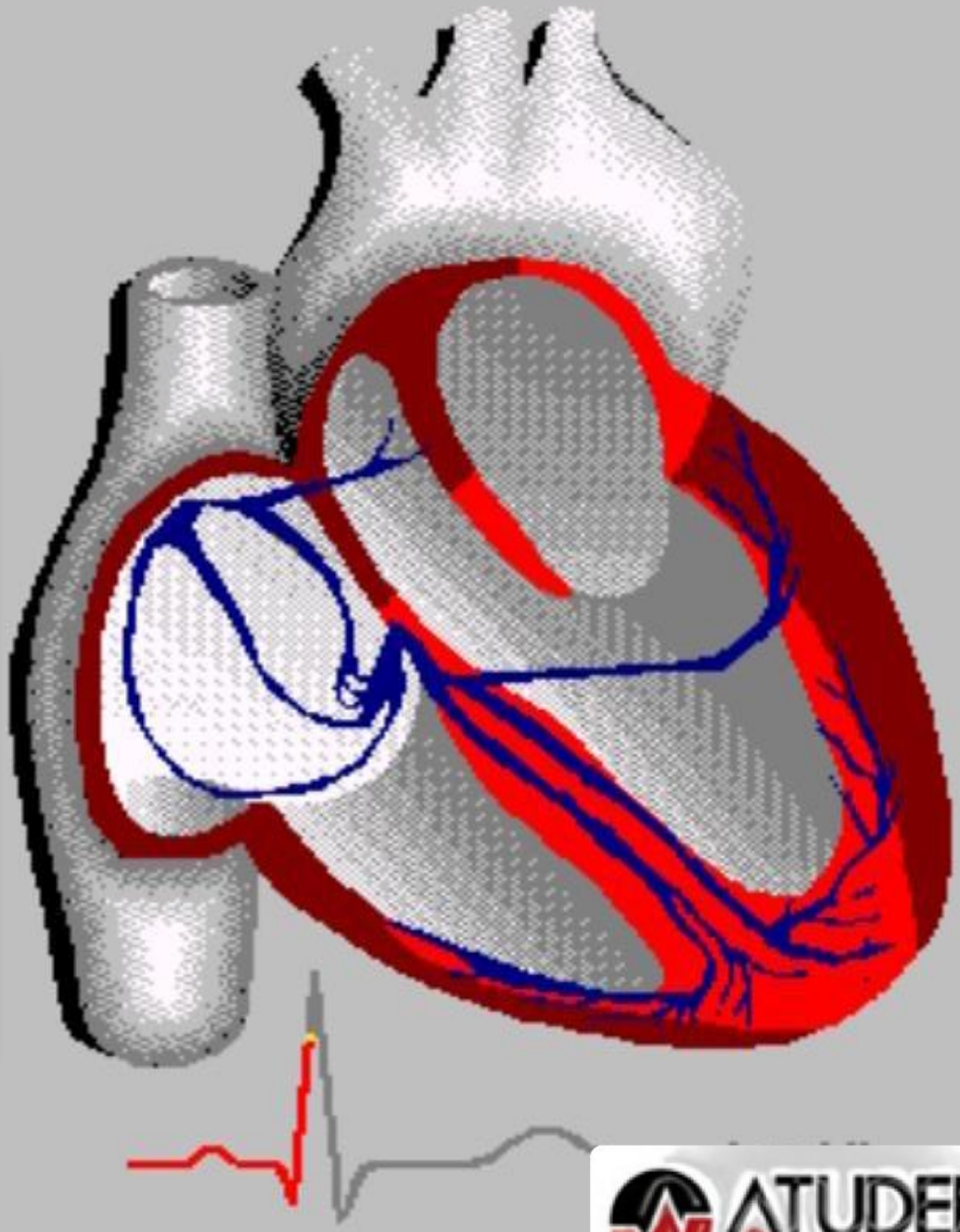

Ventrikül depolarizasyonun tamamlanması

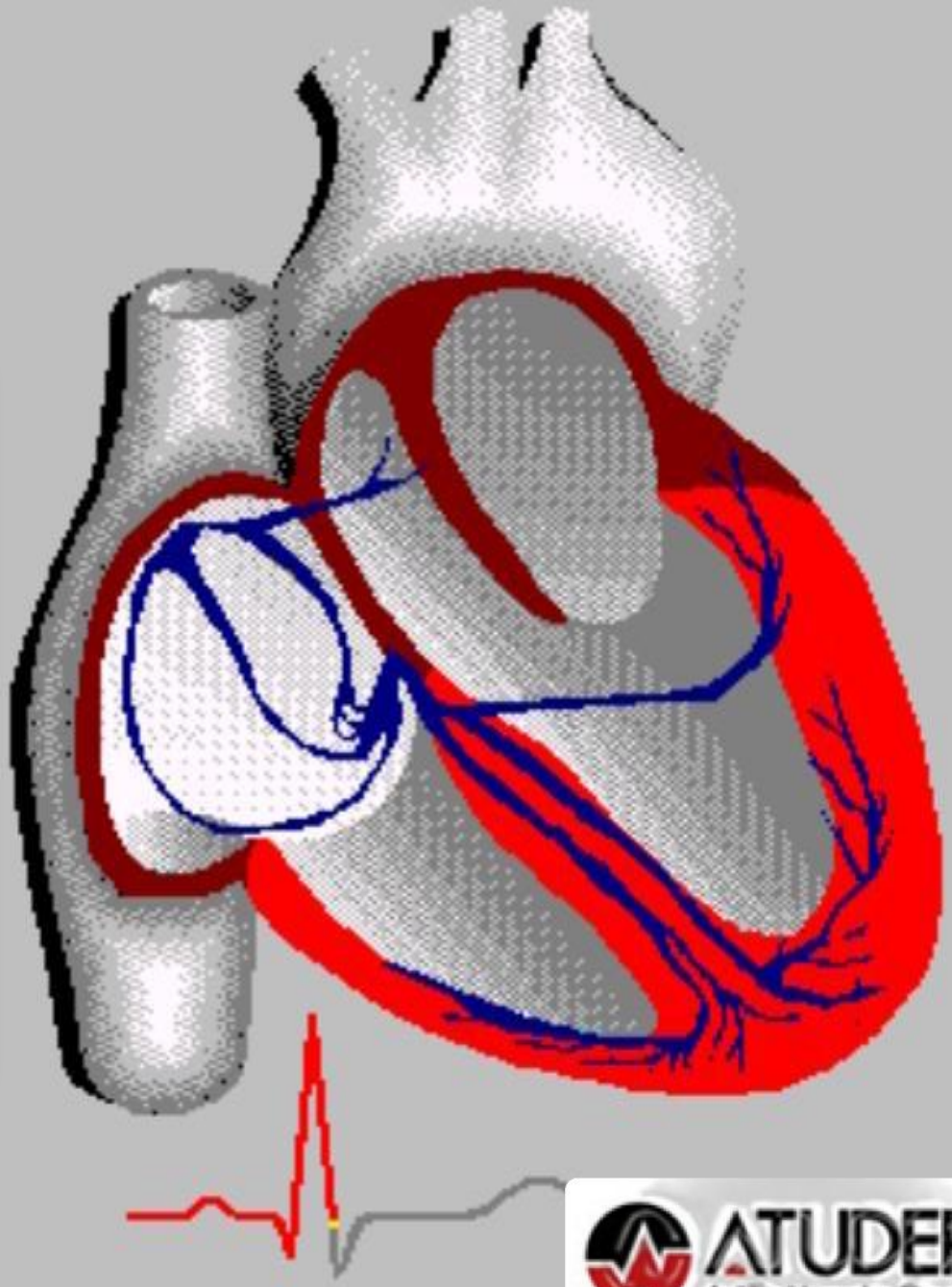

Posterobazal kısımların depolarizasyonu

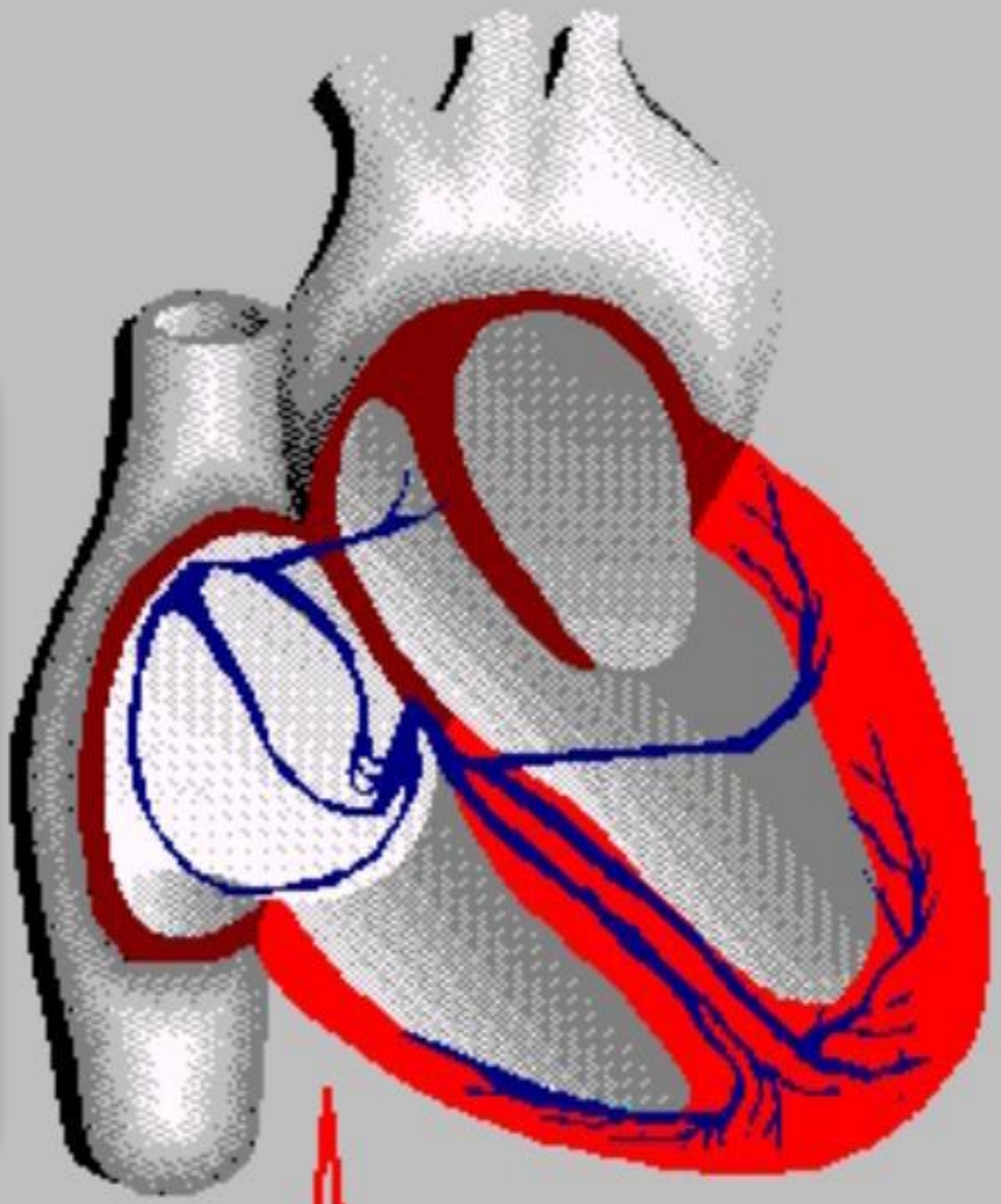

Ventrikül repolarizasyonu

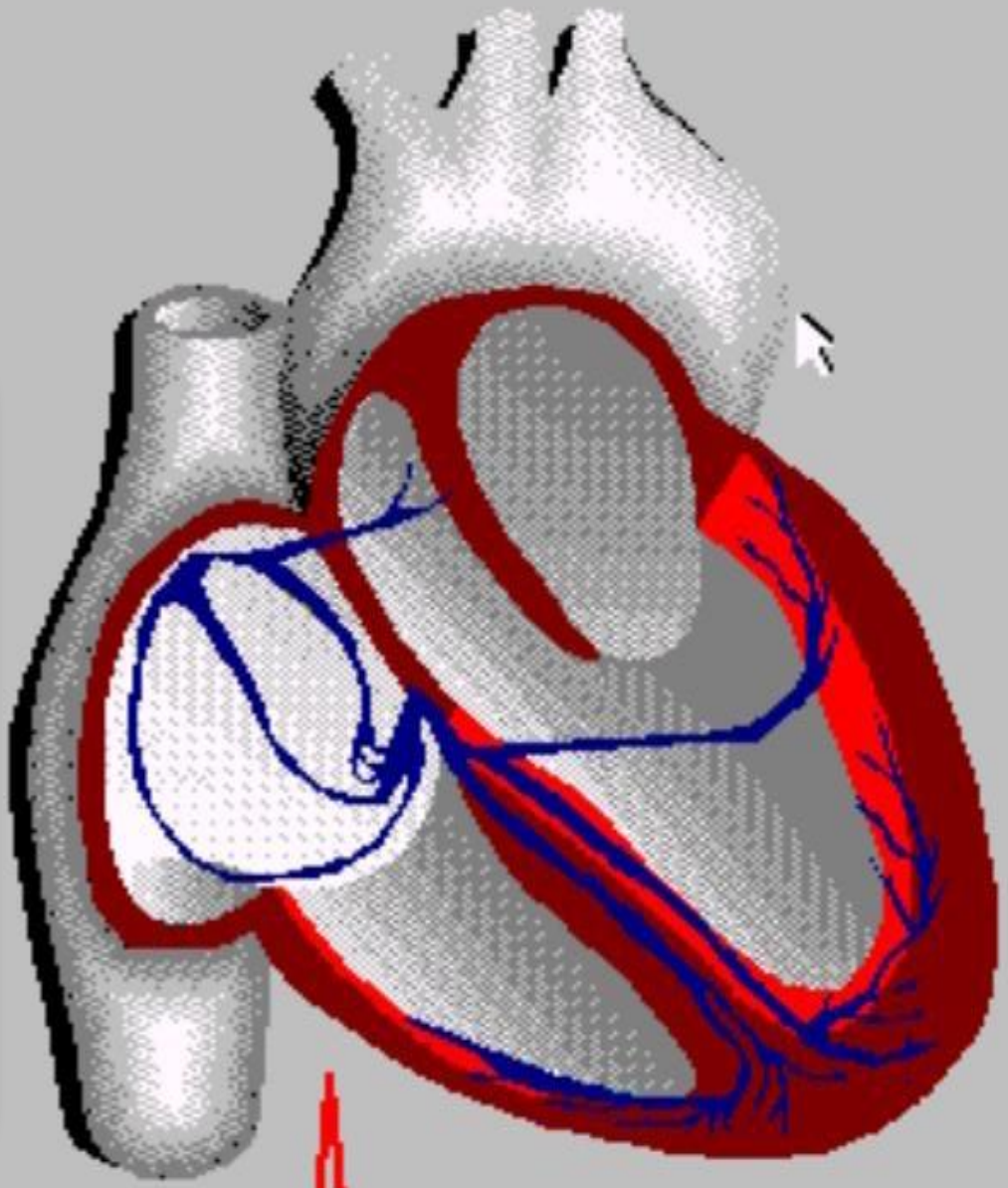

Temel EKG yorumlanması

Pacemaker bölgelerinin uyarı çıkarış hızları yukarıdan aşağıya doğru azalır.

•SA Nod	60-100/dak
•AV Nod	40-60/dak
•His-Purkinje	30-40/dak
•Ventrikül	< 30/dak

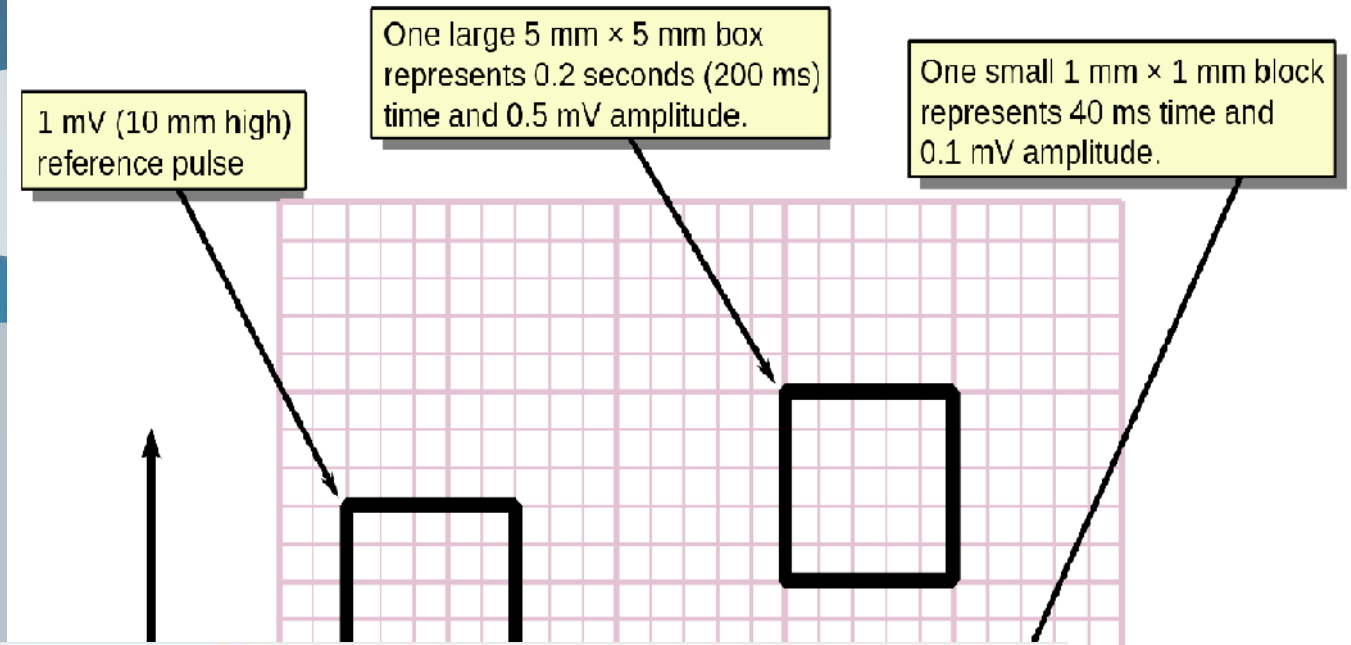
1 mV (10 mm high) reference pulse
One large 5 mm × 5 mm box represents 0.2 seconds (200 ms) time and 0.5 mV amplitude.
One small 1 mV × 1 mm block represents 40 ms time and 0.1 mV amplitude.

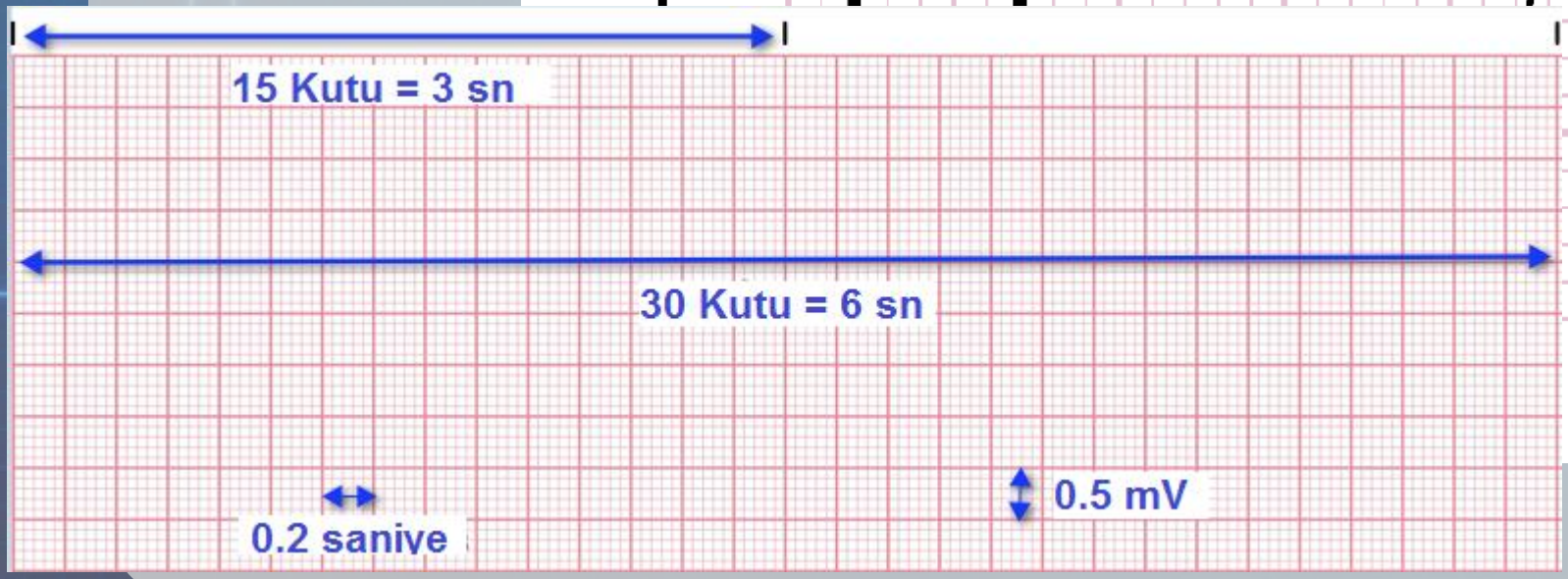
15 Kutu = 3 sn
30 Kutu = 6 sn
0.5 mV
0.2 sanive

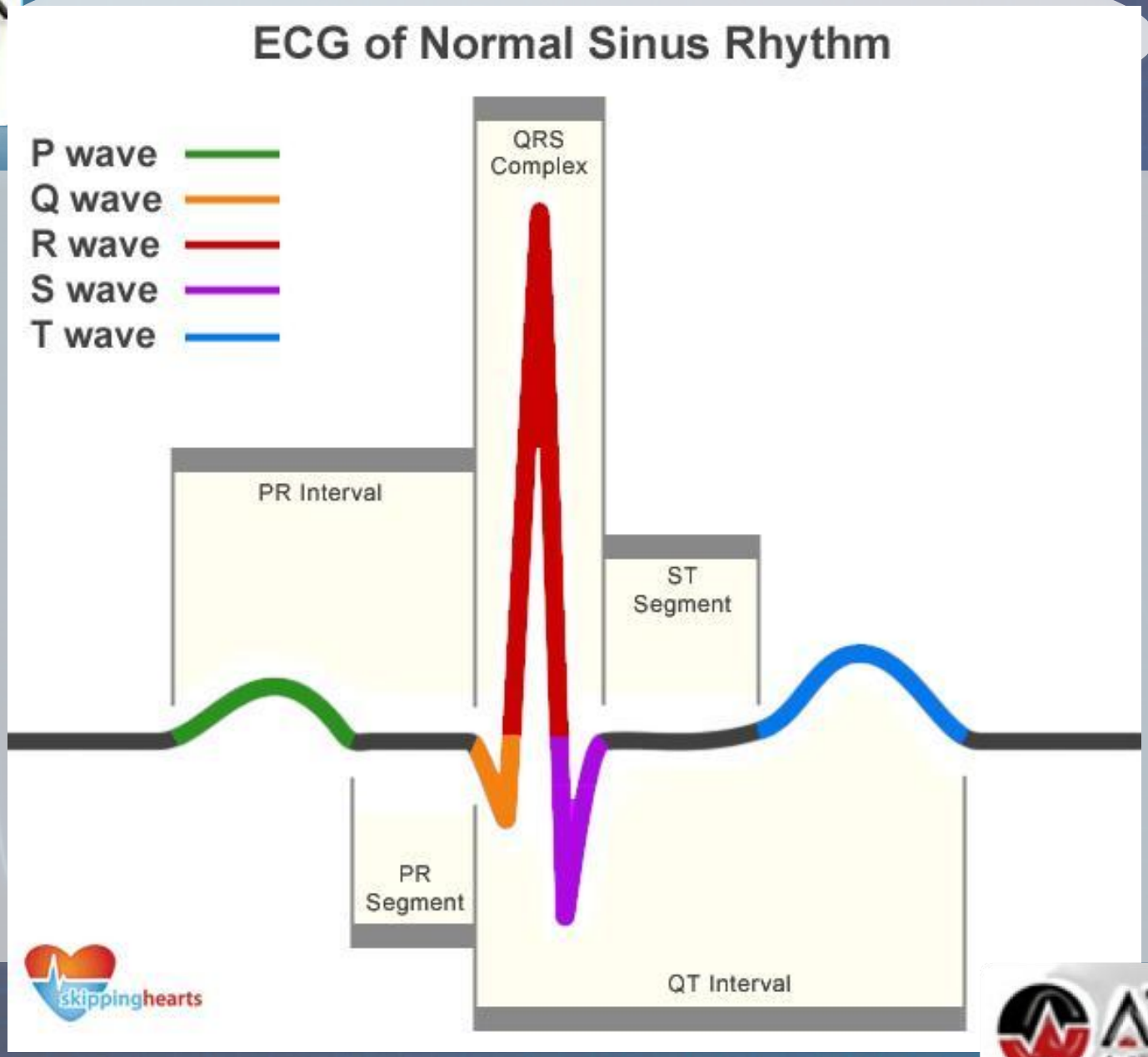
ECG of Normal Sinus Rhythm
P wave
Q wave
R wave
S wave
T wave
QRS Complex
PR Interval
ST Segment
PR Segment
QT Interval
skippinghearts

EKG Şeridinin Yorumlanması

- Ritim
- Hız
- P Dalgası
- P-R İntervali
- QRS Kompleksi
- ST segmenti
- Derivasyon okuma

RİTİM

- Ritim düzenli mi?

R-R intervallerinin düzenli olup olmadığı incelenir

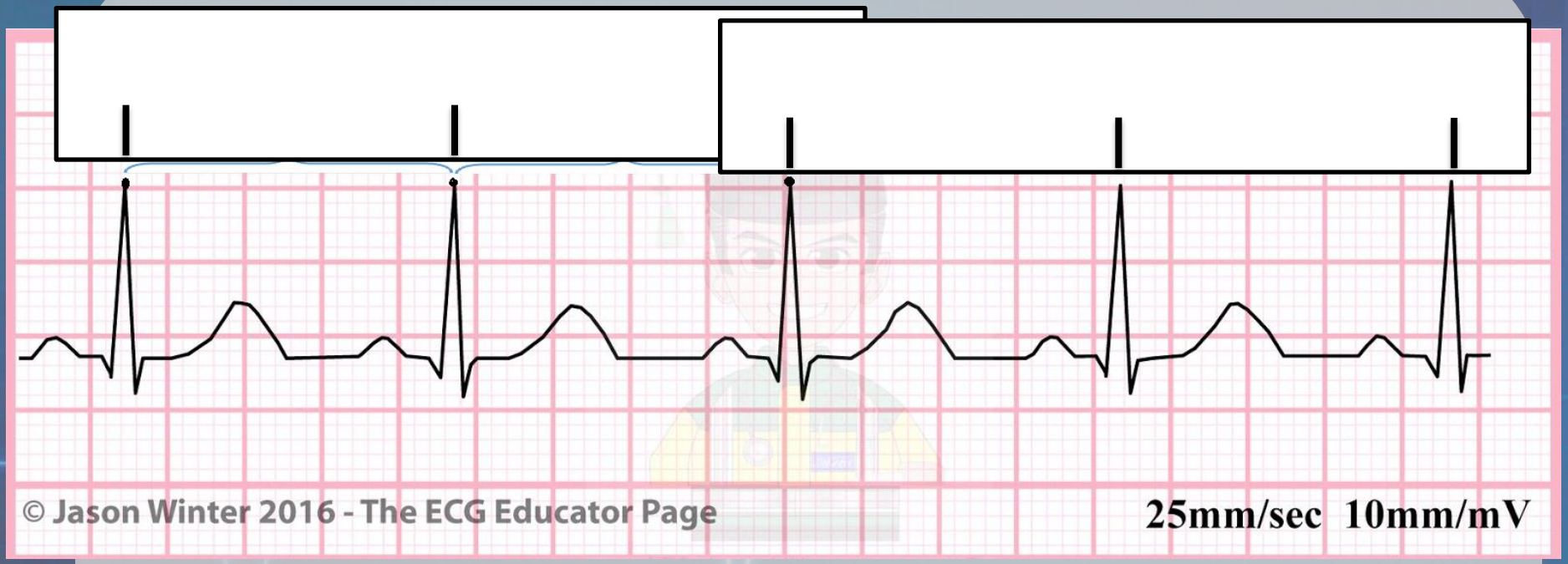
© Jason Winter 2016 - The ECG Educator Page
25mm/sec 10mm/mV

HIZ

Bradikardi <60 Normal 100> Taşikardi

EKG H

R-R intervaline gö

•300 / büyük kare

•1500 / küçük kar

Ritim düzensiz is

•15 tane büyük ka

toplanarak 20 ile ç

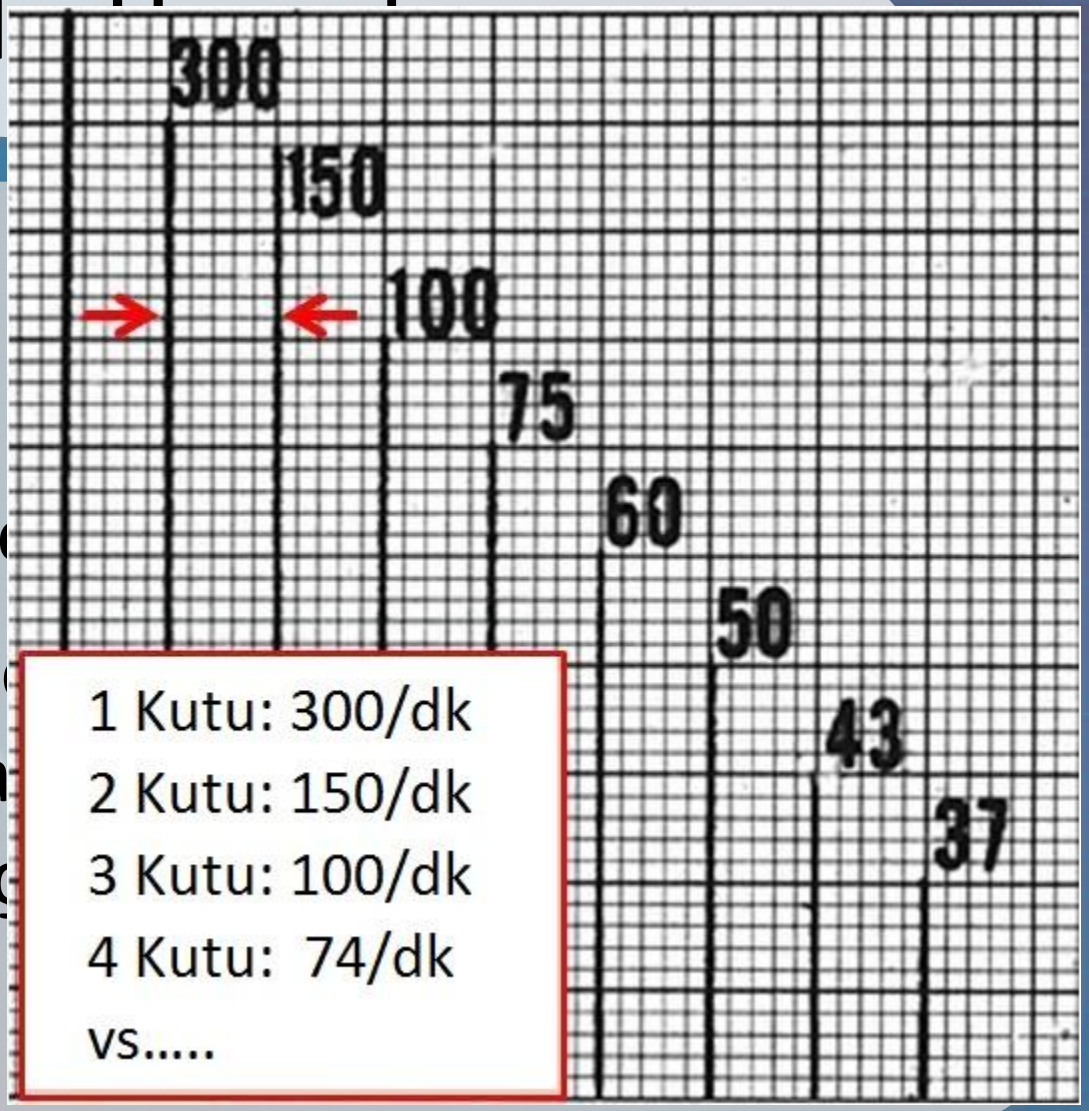

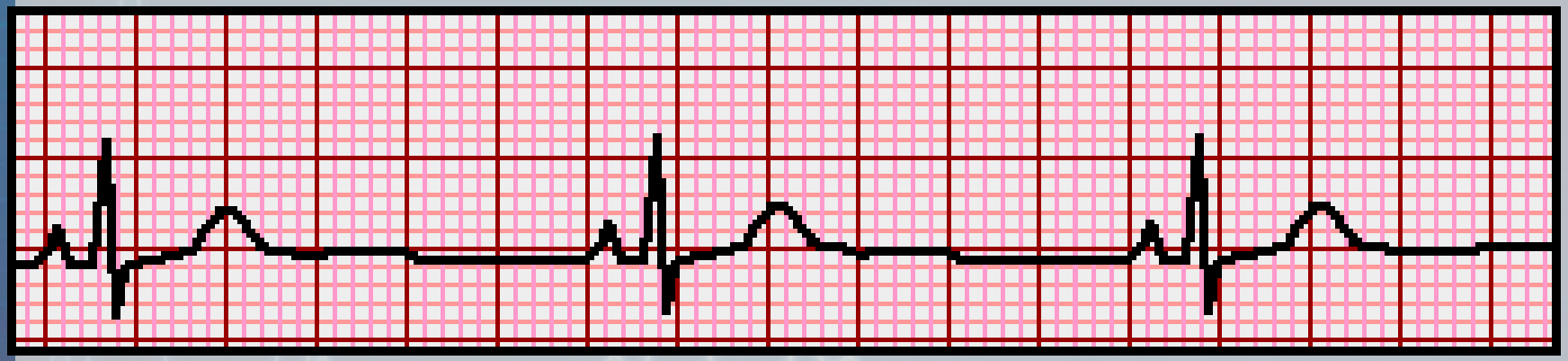

300\6 = 50 atım

Pratik olarak:
1 dk da 300 büyük kare geçer.
1 dk da geçilen büyük kare sayısının, 1 atımda geçilen büyük kare sayısına bölünmesi

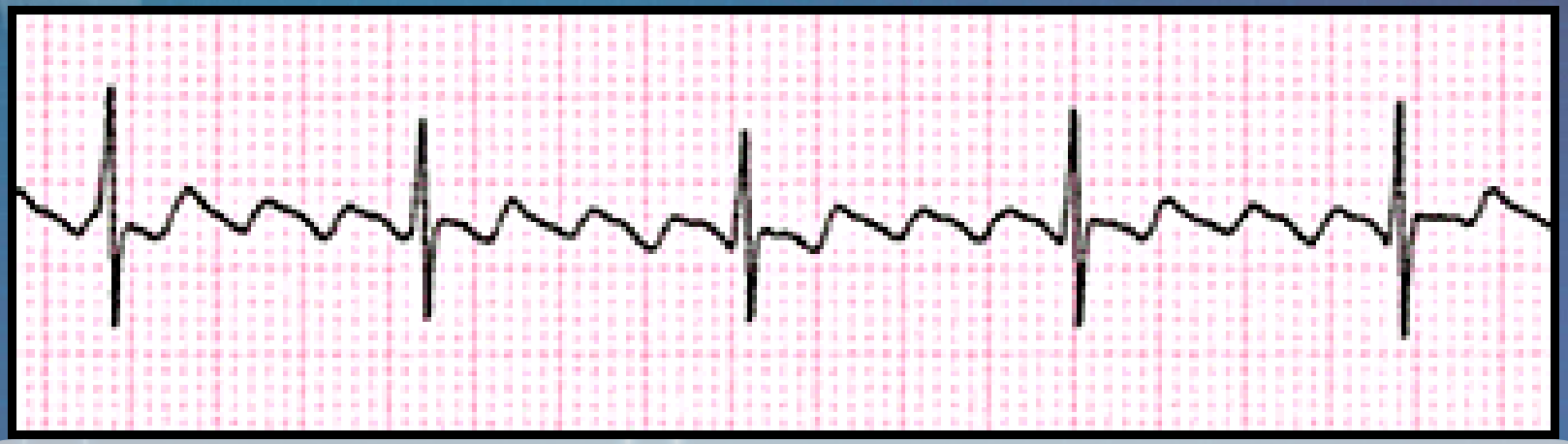

(300 / ~ 4) = ~ 75

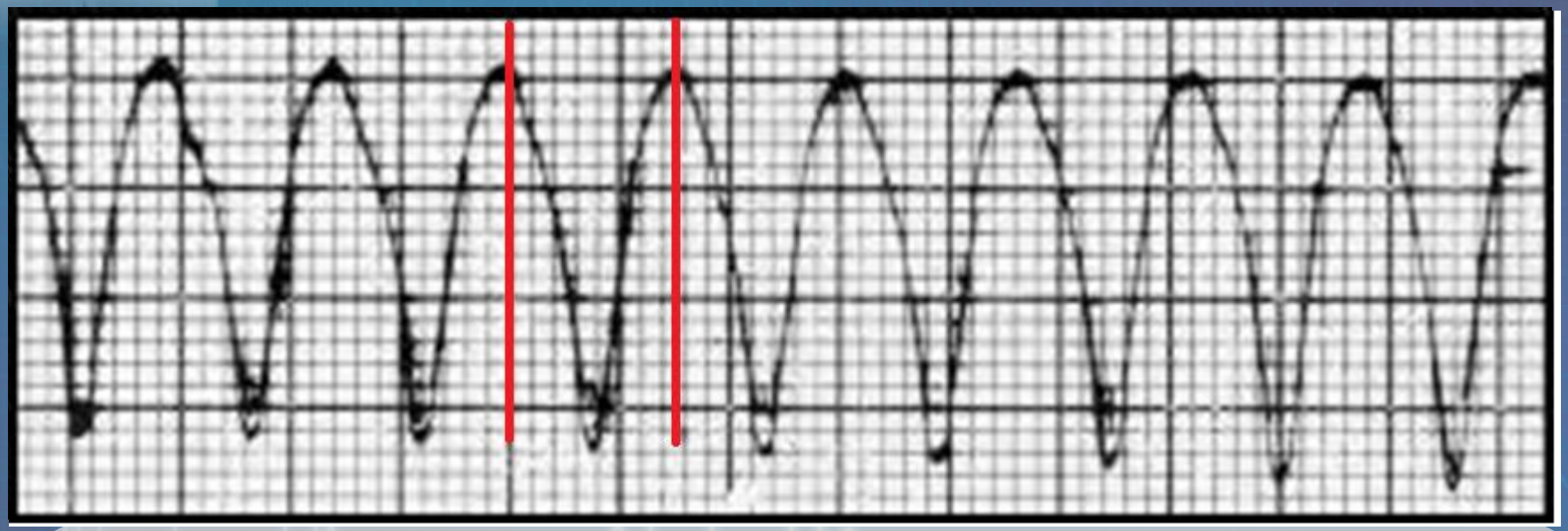

(300 / 1.5) = 200

P DALGA ANALİZİ

- 100
- P d
- P d
- He
- P d
-

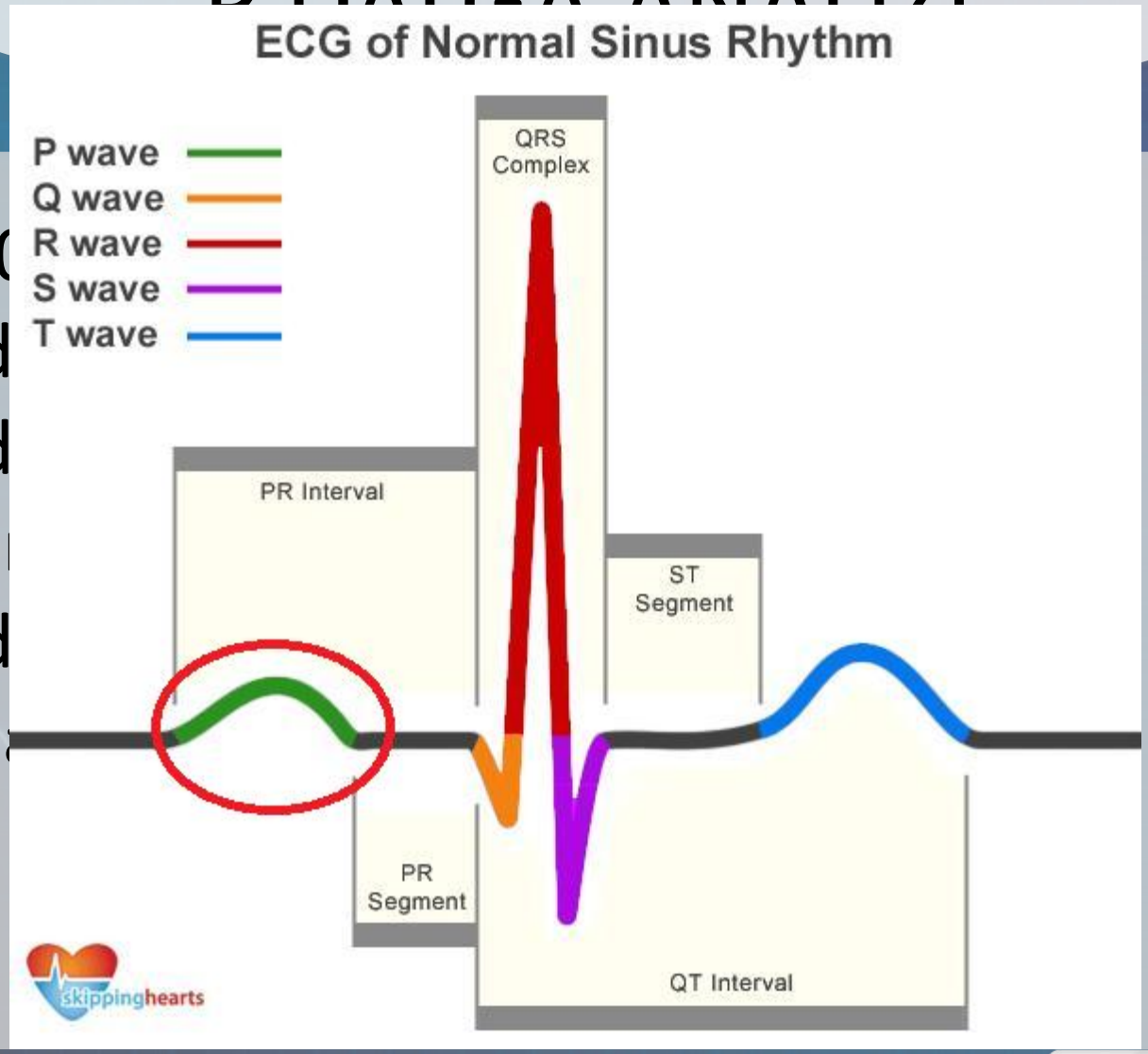

P-R İNTERVALİ ANALİZİ

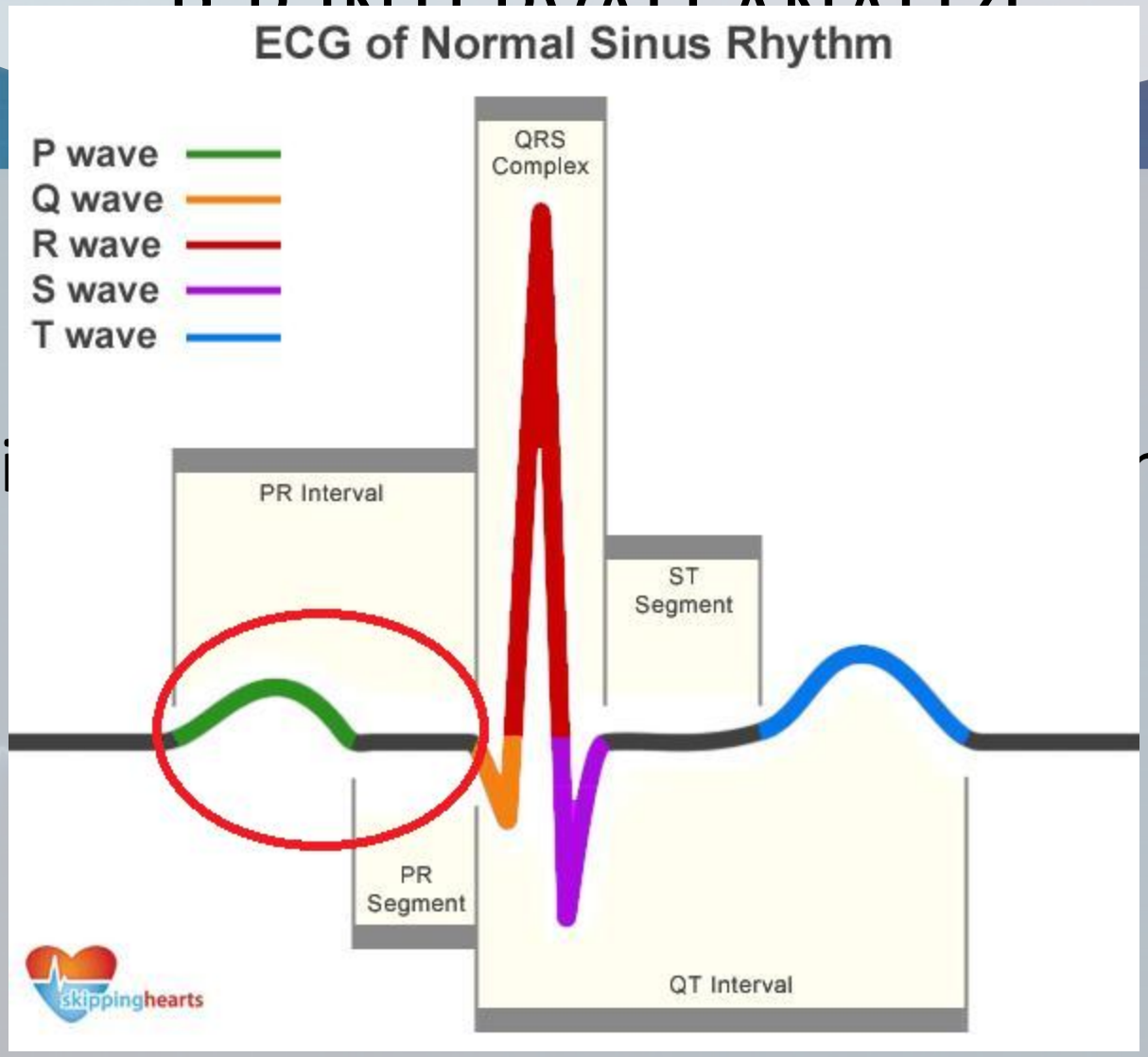

Atri… …noda

QRS KOMPLEKSİ ANALİZİ

- Bütü
- QRS'
  - -0.1
  - -Ge

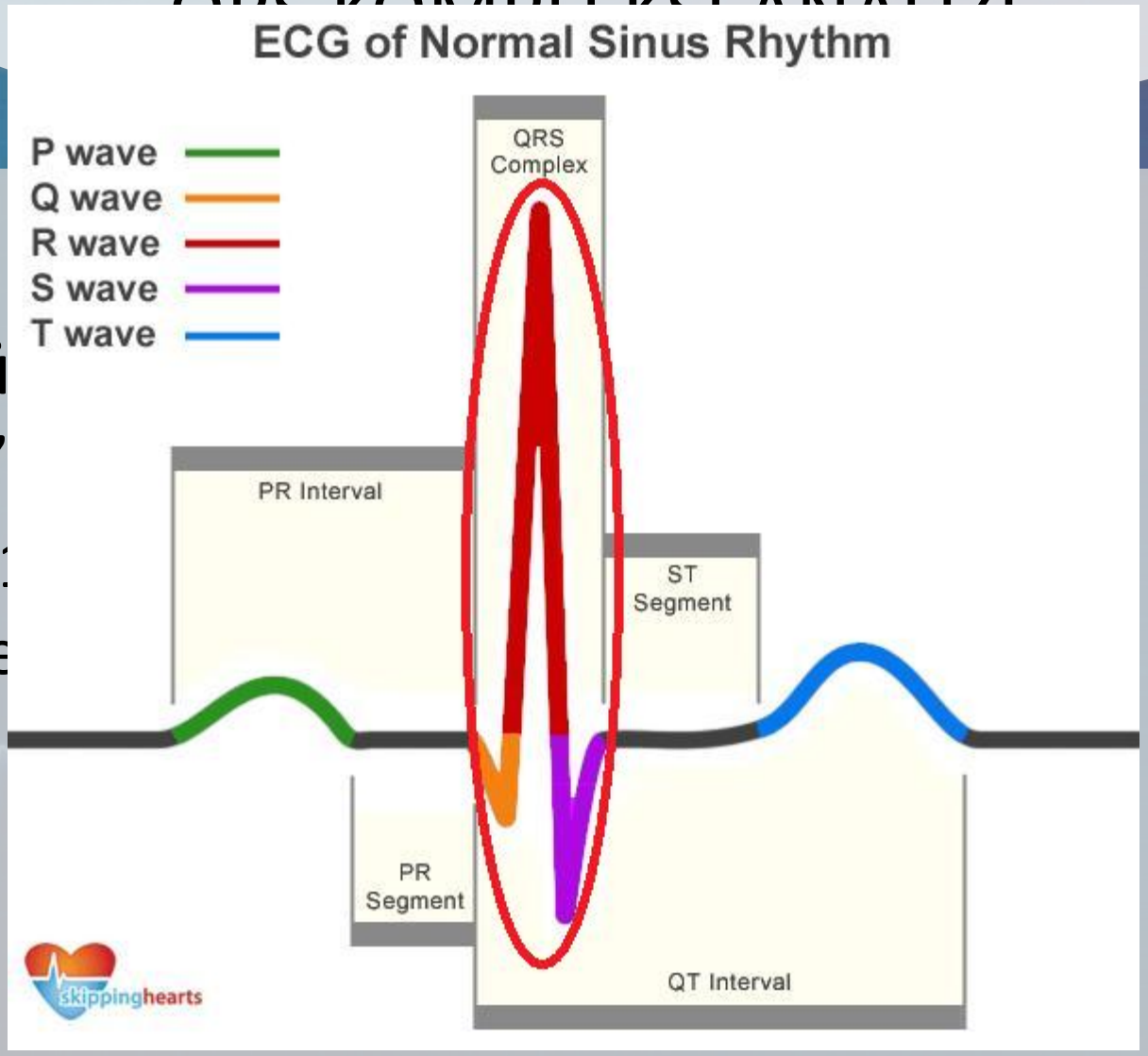

QRS KOMPLEKSİ ANALİZİ

- Süre > 0.12 sn
- Geniş QRS varlığı; sağ veya sol dal bloğunu, ventriküler ritmi veya hiperkalemiyi gösterir.
- Patolojik Q dalgaları yoktur
  - Q dalgaları; göğüs derivasyonlarında 0.04sn. den kısa olmalı

ST SEGMENT ANALİZİ

- QR
  baş
  böl
- No
- ST
  inn
  der
- ST

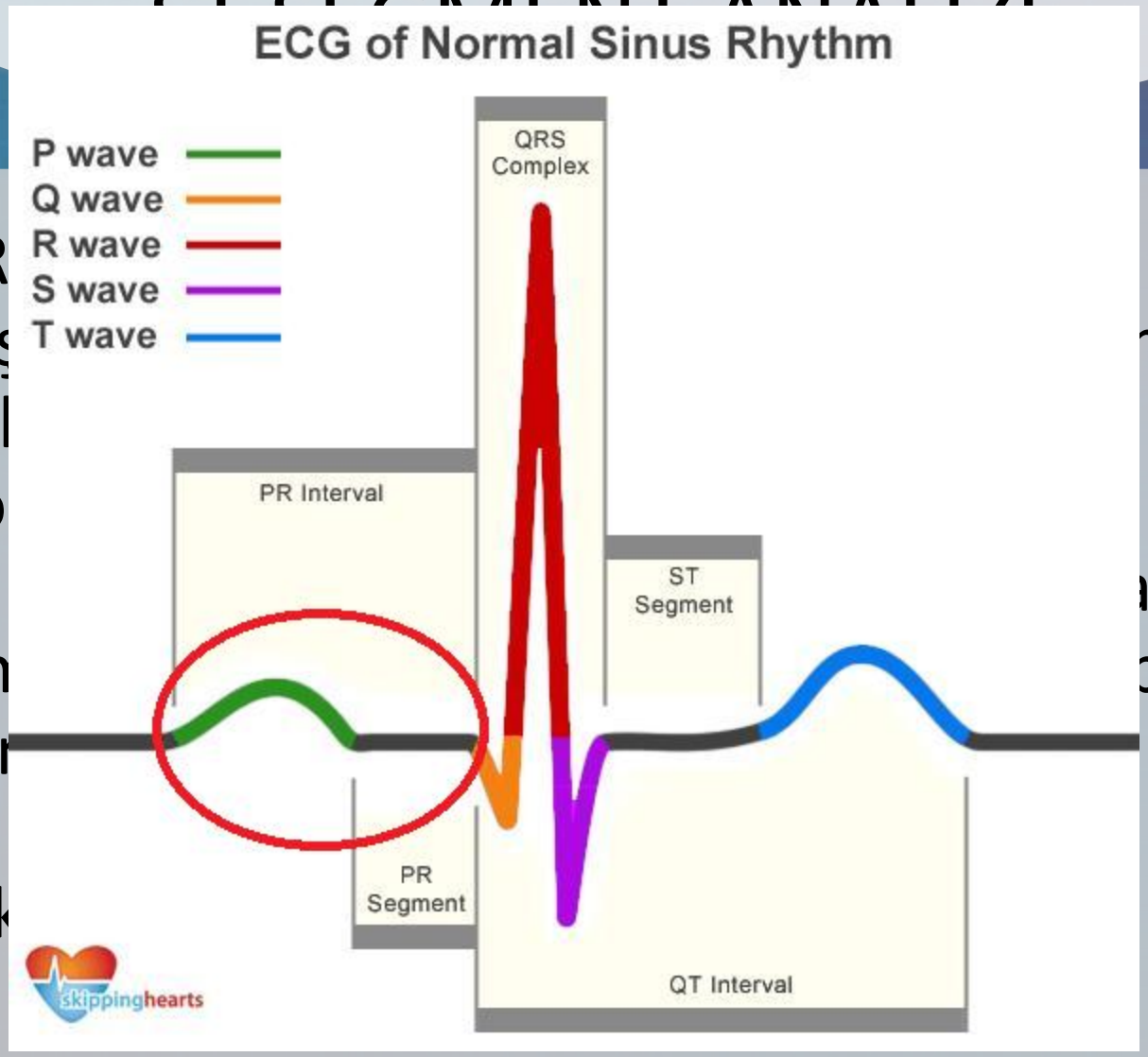

n

a

oması

fazla

QT İNTERVALİ

- Q d… nuna kad…
- Ve… rep…
- Or… dir.
-
- Hip… ısalır.

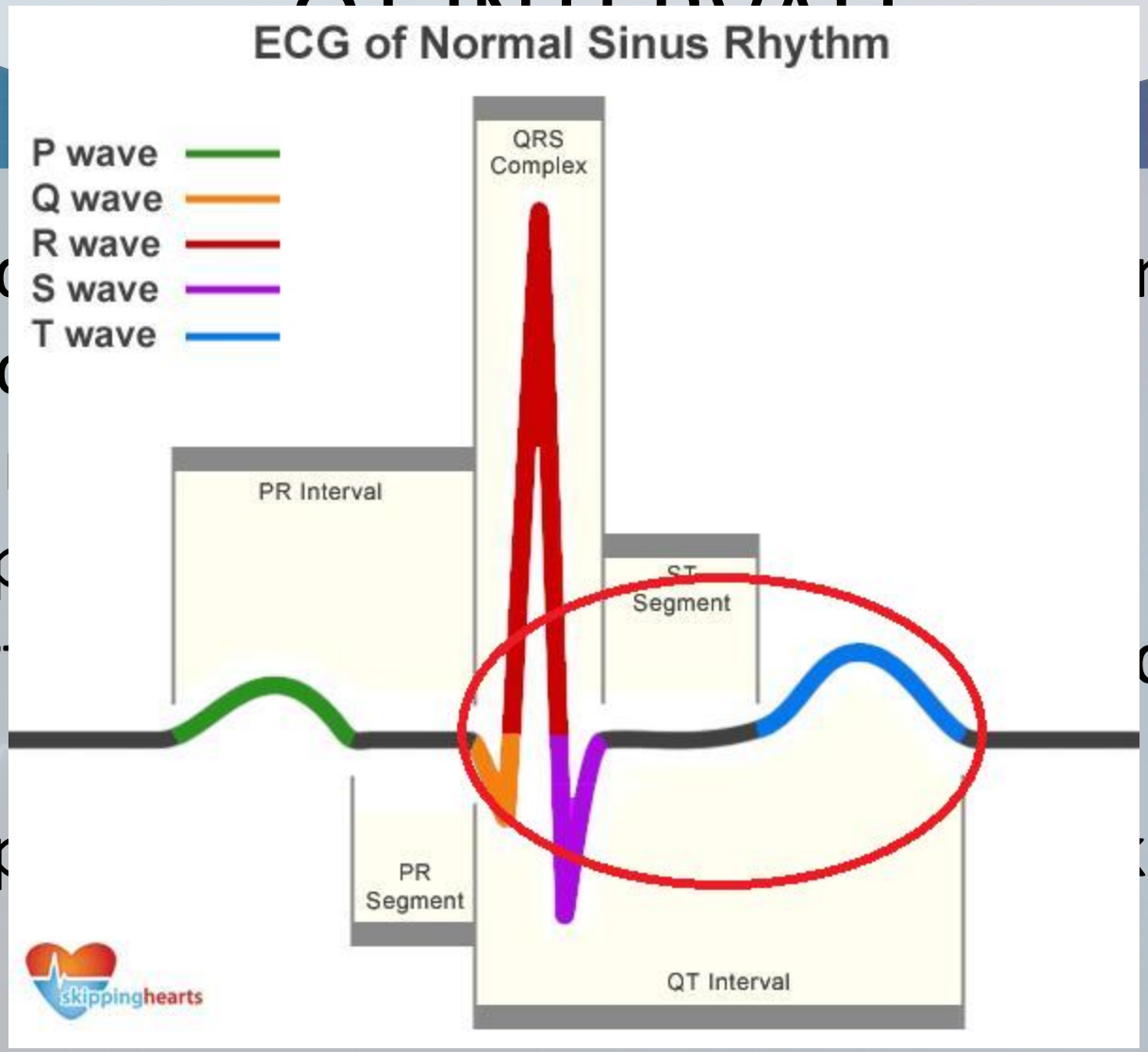

The 12 lead ECG:

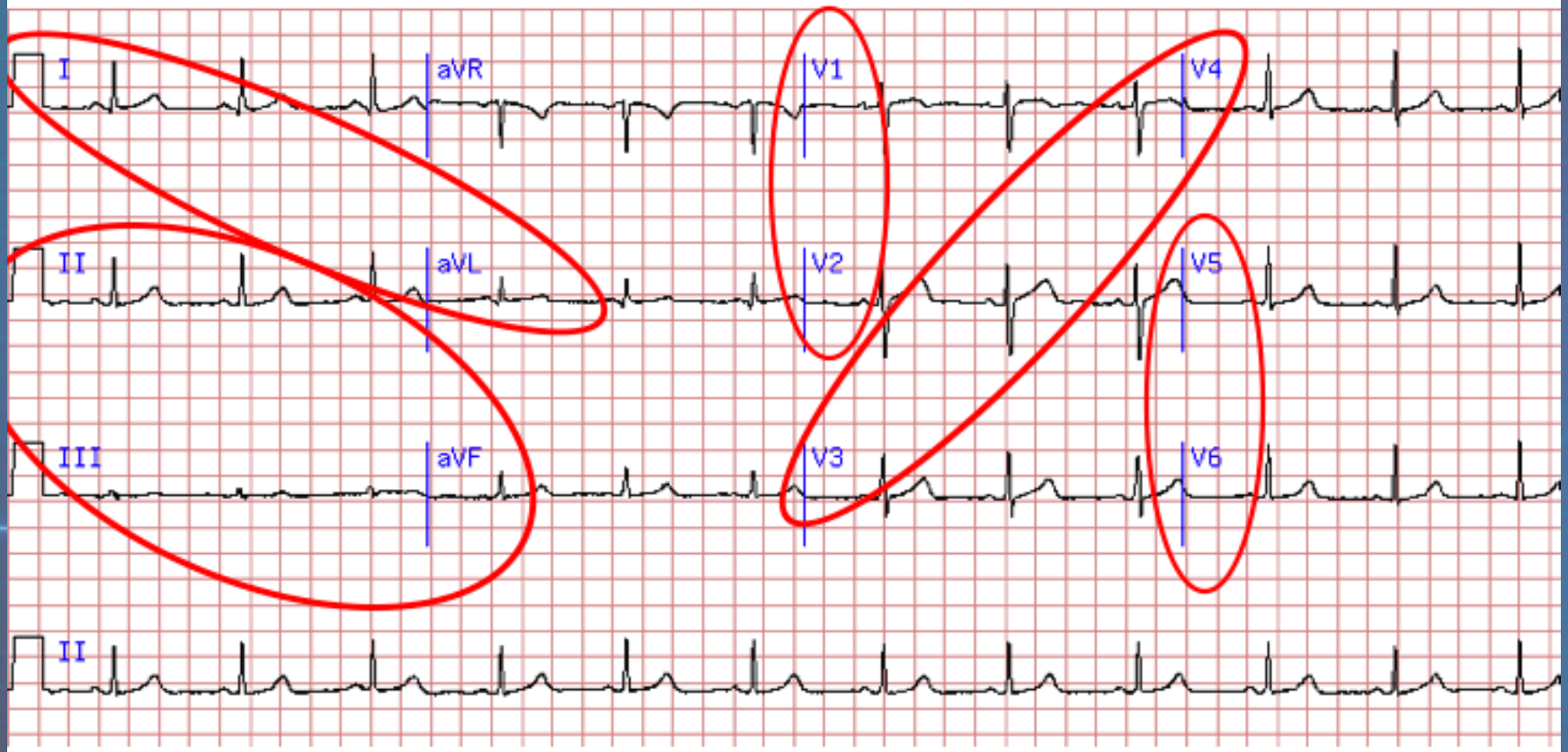

Normal Ritim?

Sinüs Nodundan kaynaklanarak atriyumları uyardıktan sonra AV noddan geçerek his purkinje yolu ile ventrikülleri uyaran ritme denir.

EKG Özelliği:
- Düzenli bir ritim
- Hız 60-100 /dak.
- Normal bir P dalgası
- QRS dar olacak ve p ile düzenli bir ilişki
- ST segmenti izoelektirk hatta olacak -/+ olmayacak

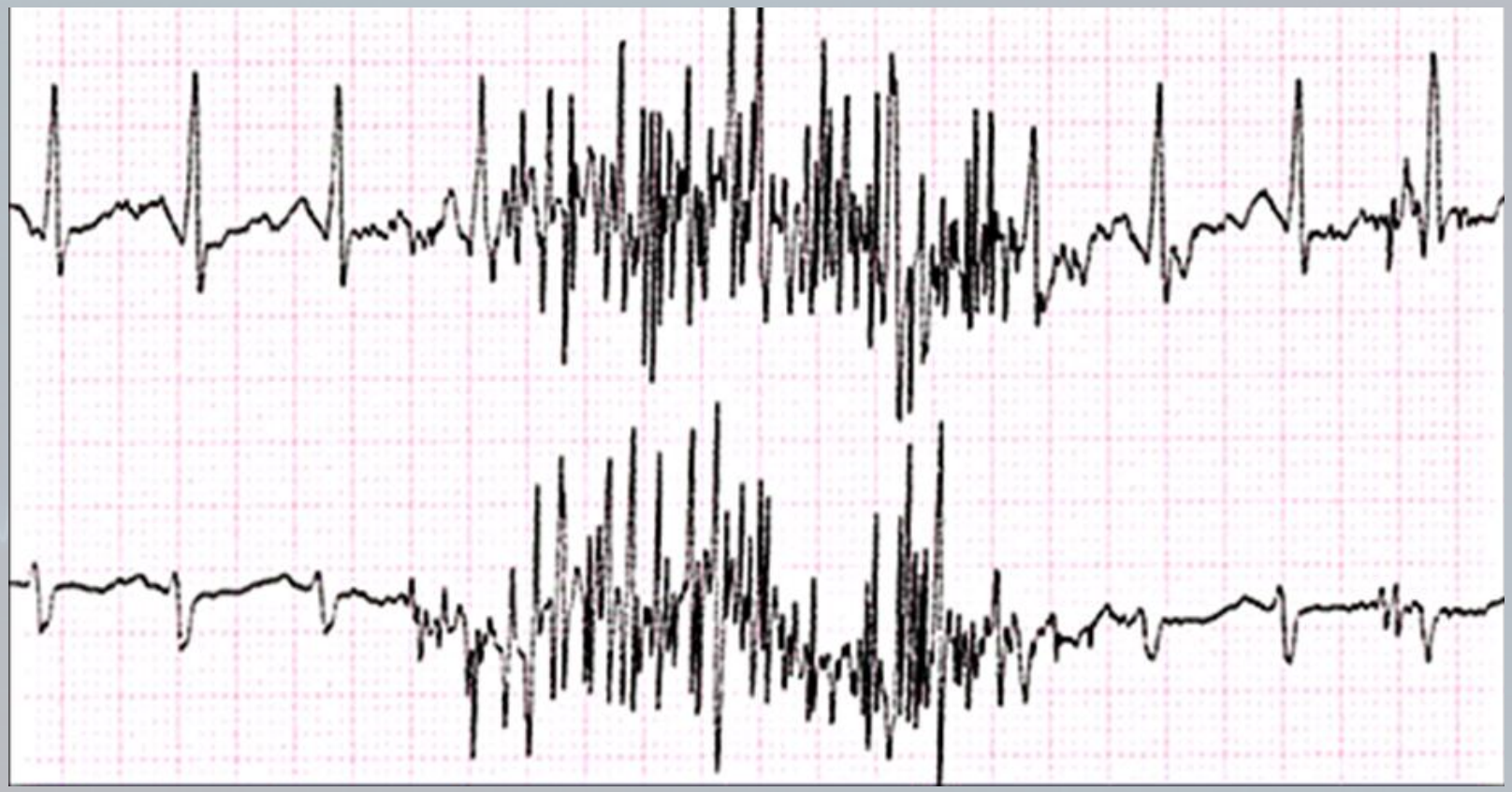

Olgu

- Orta yaşlarda Kadın Hasta
- Göğüs ağrısı
- Kardiyak hikayesi negatif

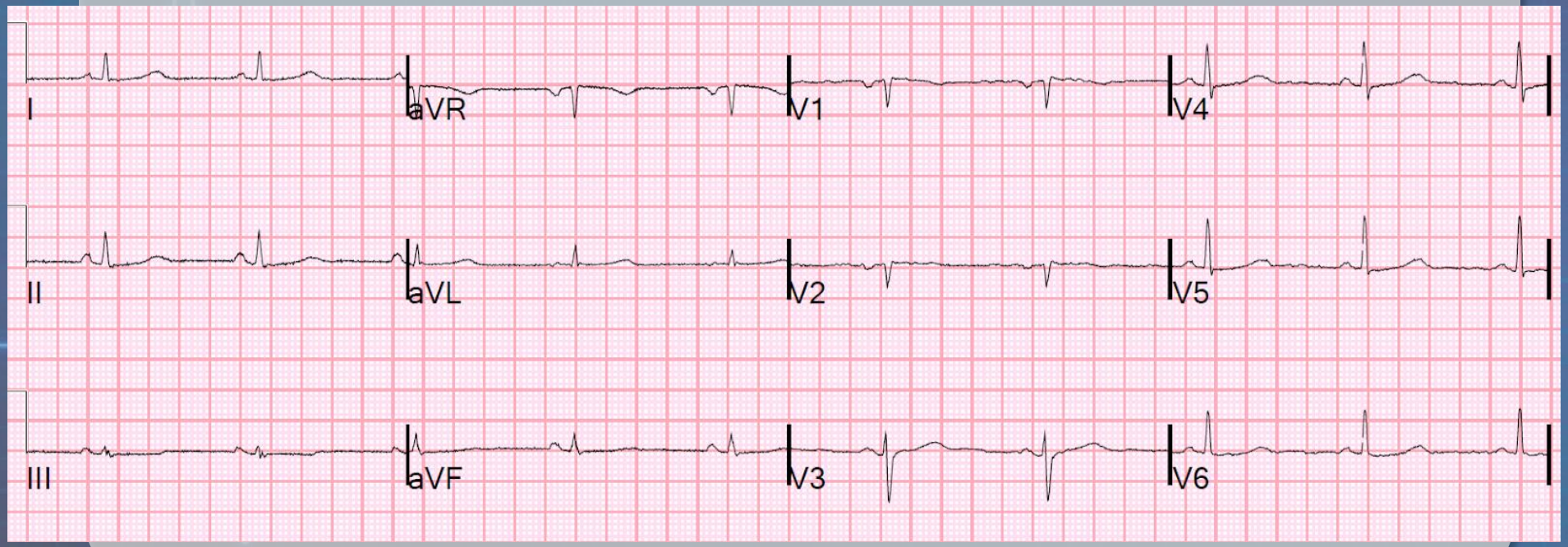

Yanlış derivasyon yerleşimi
Yüksek V1-V2

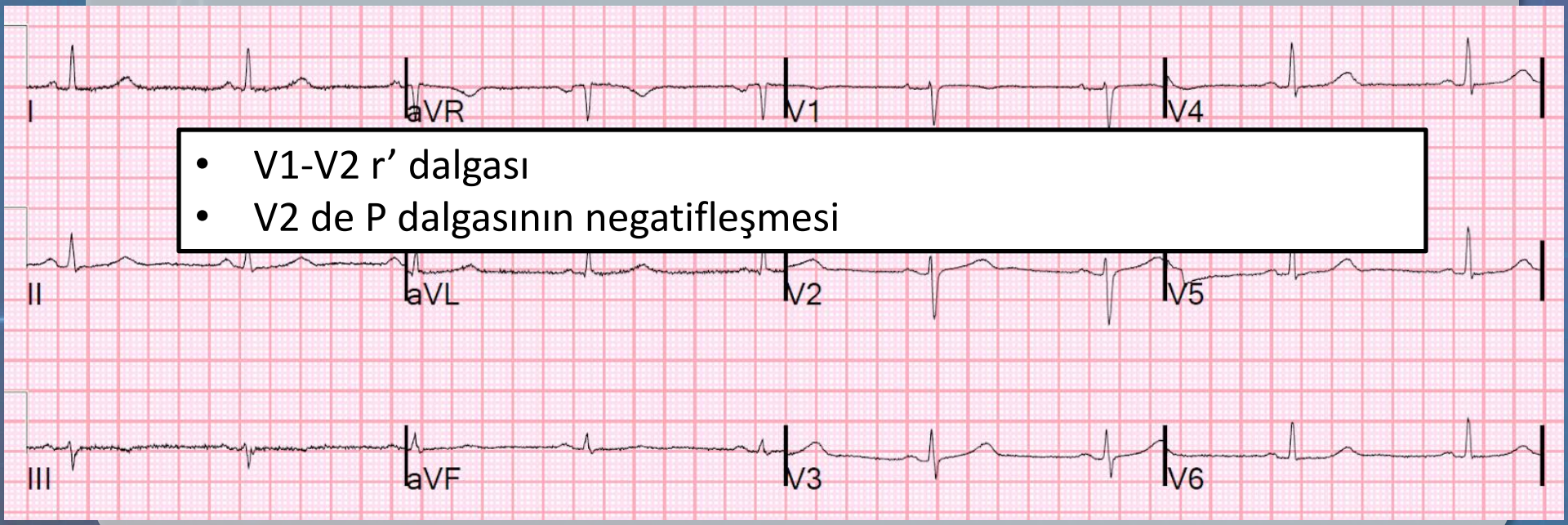

- V1-V2 r’ dalgası
- V2 de P dalgasının negatifleşmesi

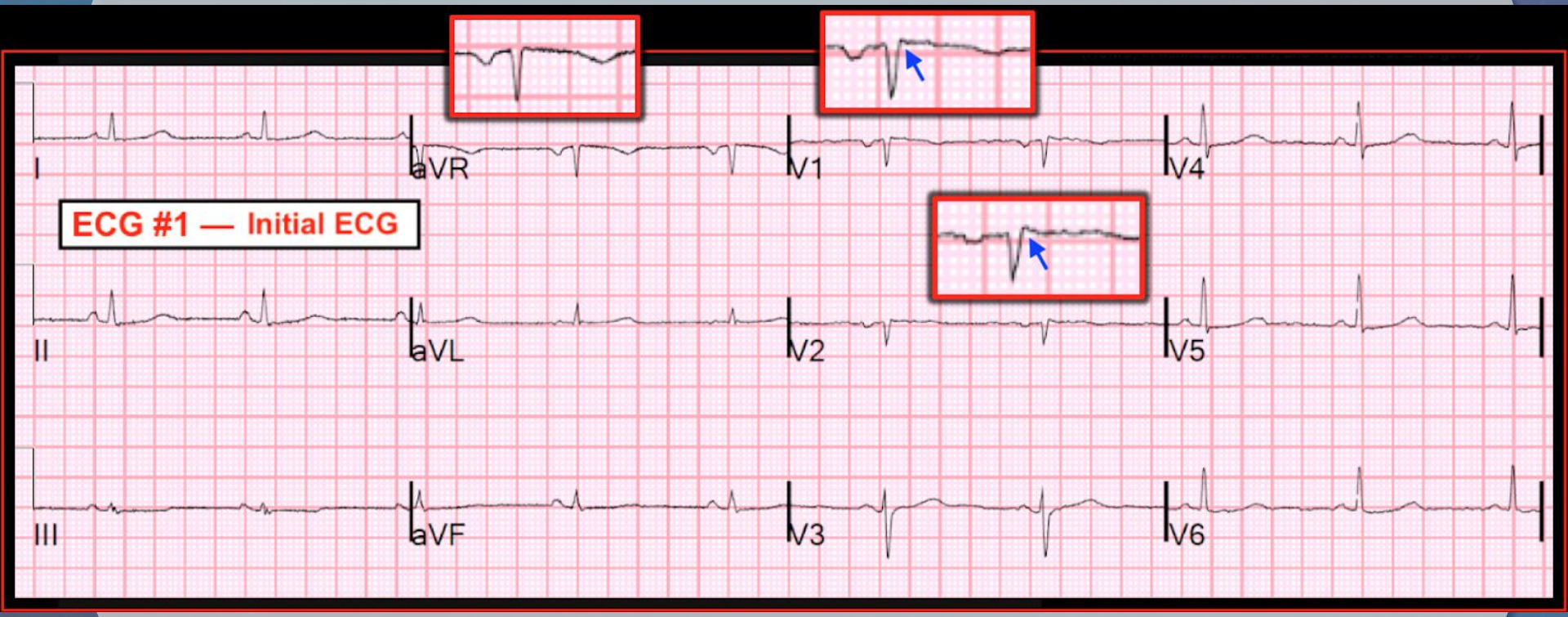
ECG #1 — Initial ECG
I
aVR
V1
V4
II
aVL
V2
V5
III
aVF
V3
V6

TEŞEKKÜRLER…